



Complex Anterior Segment Made Simple

Cullen Ryburn, MD



Winter Ophthalmic Summit 2026

Financial disclosure

1. The course material and information were created independently
2. The course material was created independently from any influence of commercial interest.
3. Financial disclosures below

Greenman Vision Inc – Investor

Alcon – Honorarium/speaker

True North Contract Resource Organization - Investor



Conversation about IOL Options



CATARACT



Topics

Small Pupils

What causes them

Floppy Iris

How to avoid them



Small Pupils

Make short cases longer

Add stress

Biggest risk factor for vitreous prolapse

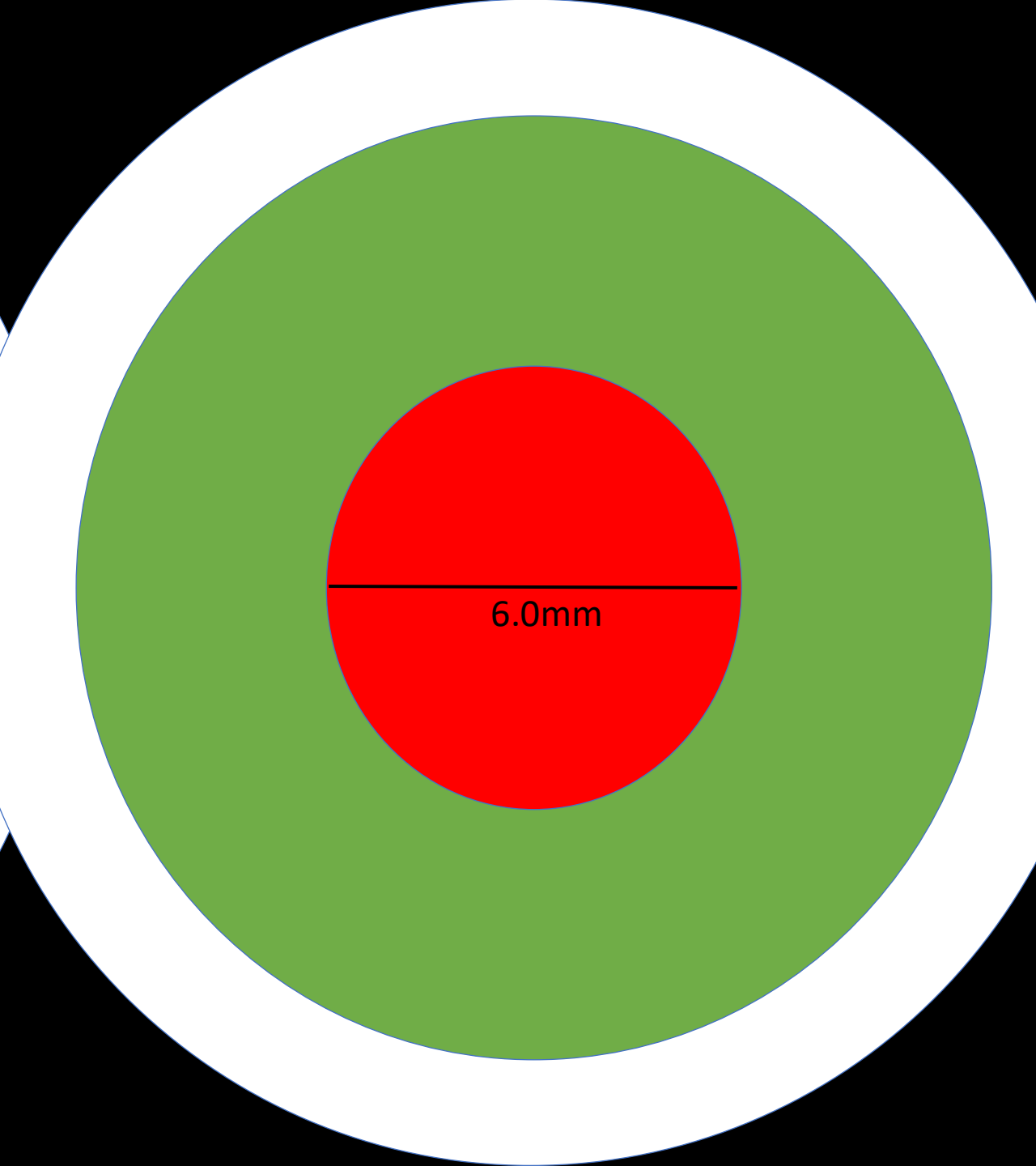
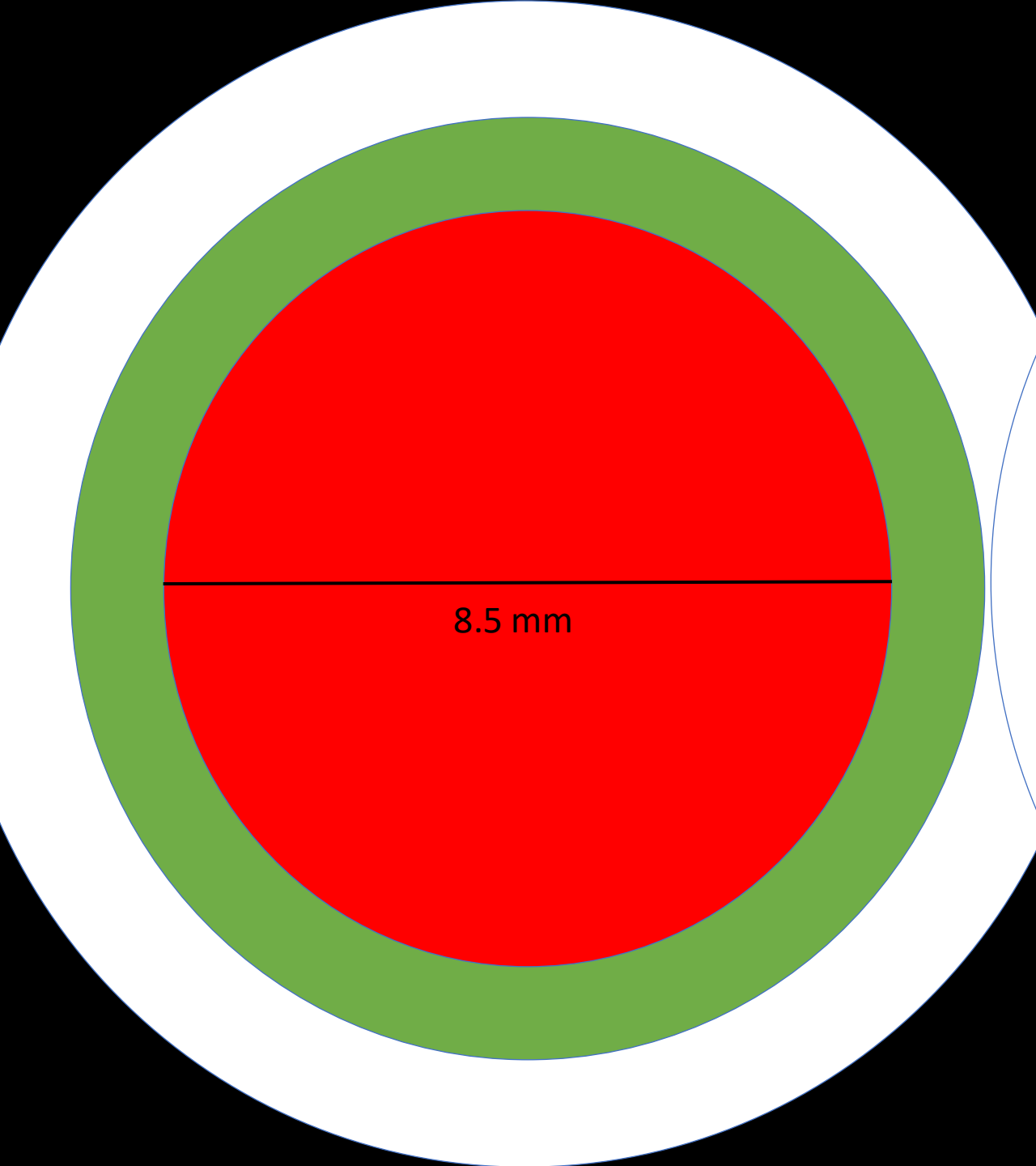


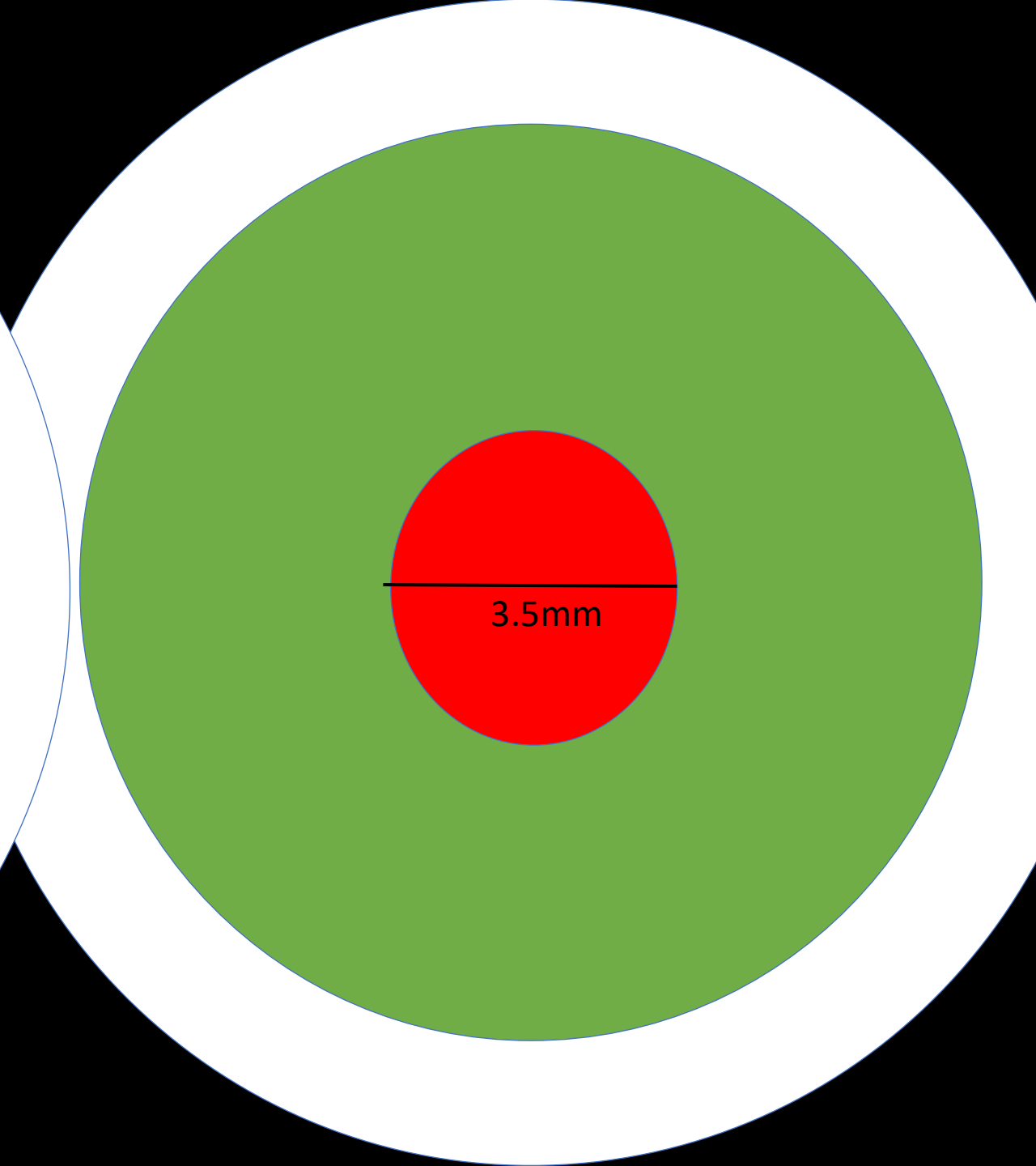
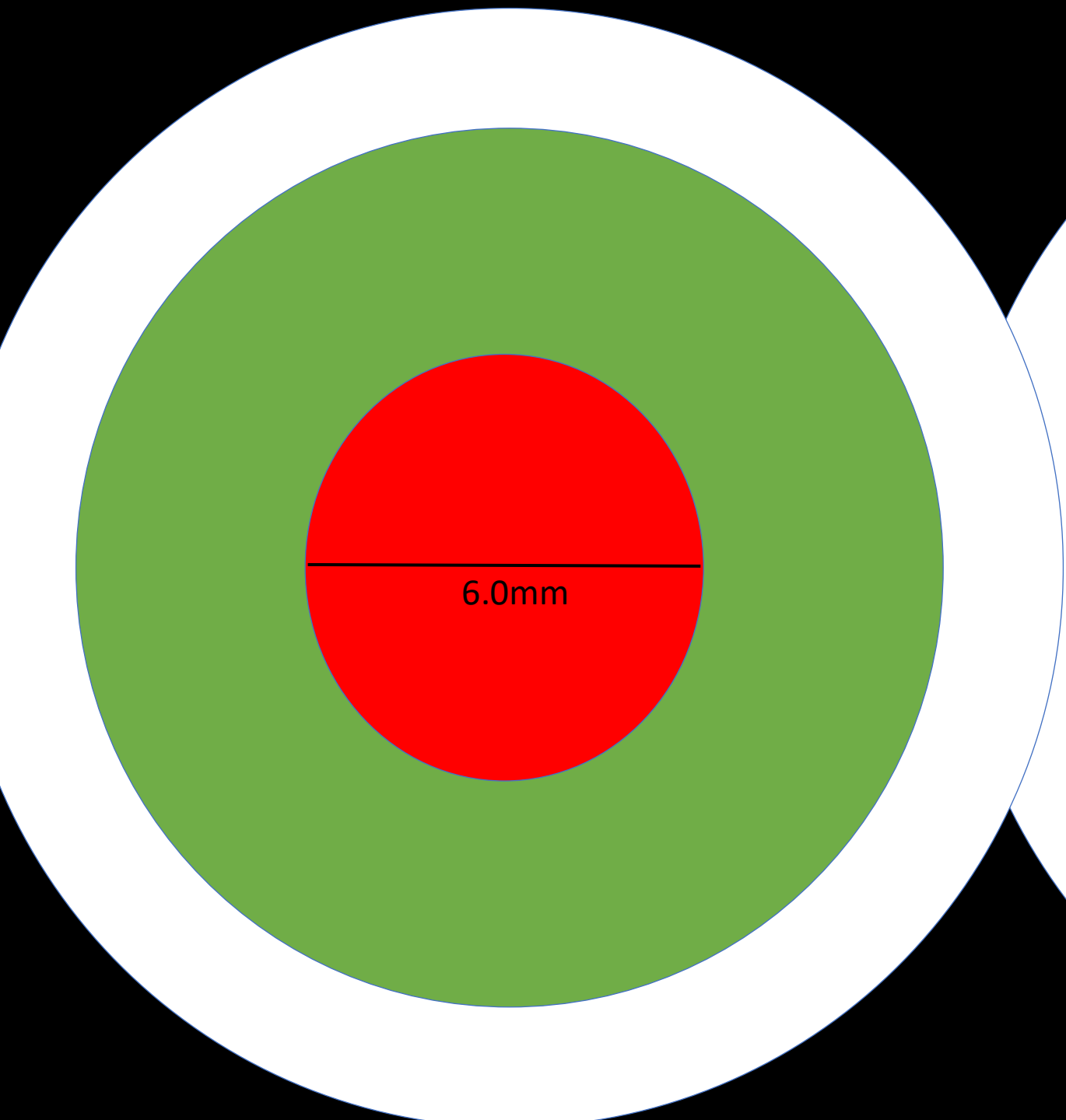
Small Pupils

2.5 mm reduction of a 8.5 mm pupil decreases operative field by ~50%

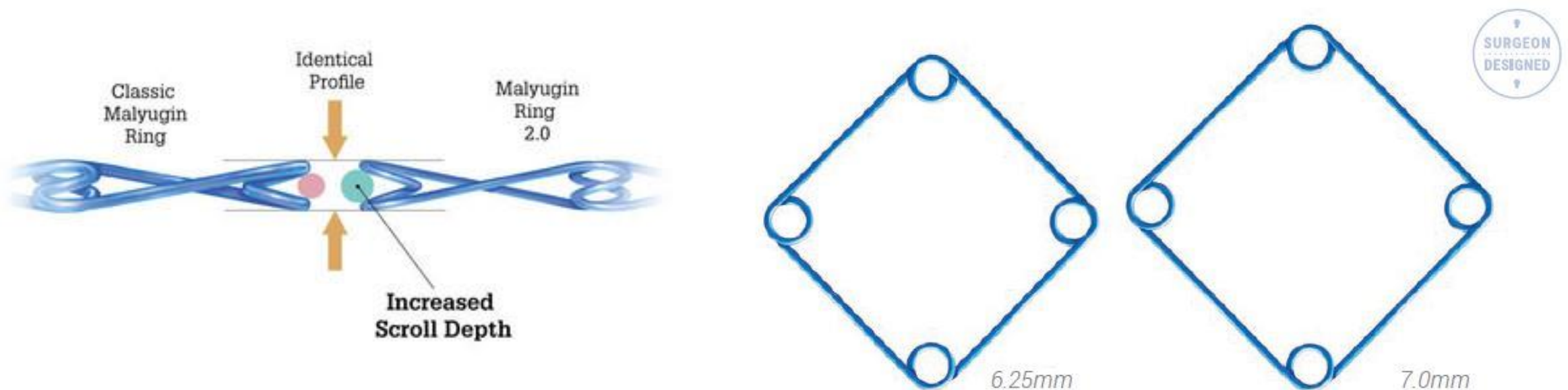
2.5 mm reduction of a 6.0 mm pupil decreases operative field by ~66%







DON'T work through a small pupil



Intraoperative Floppy Iris Syndrome (IFIS)

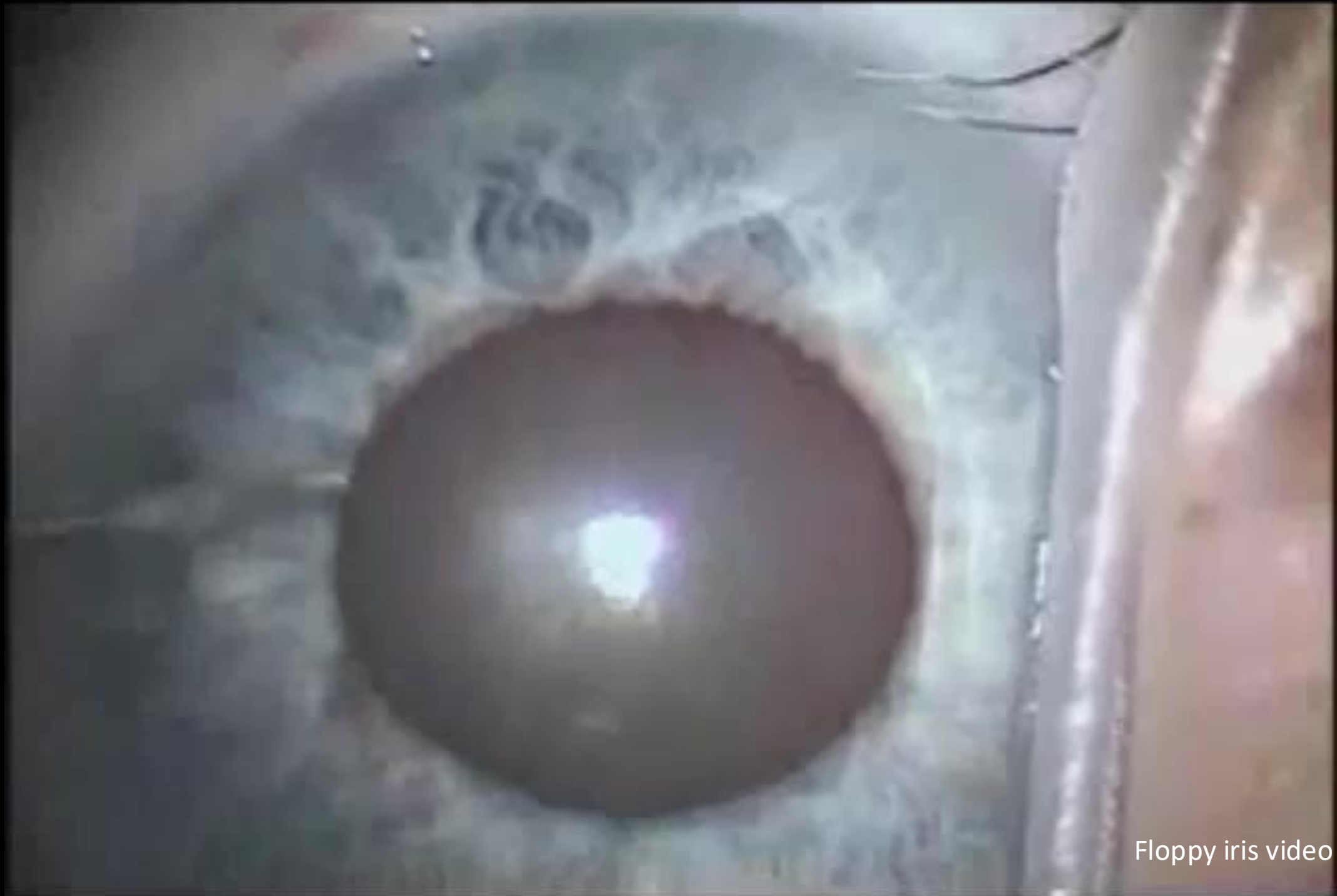Triad

Iris Billowing and Floppiness

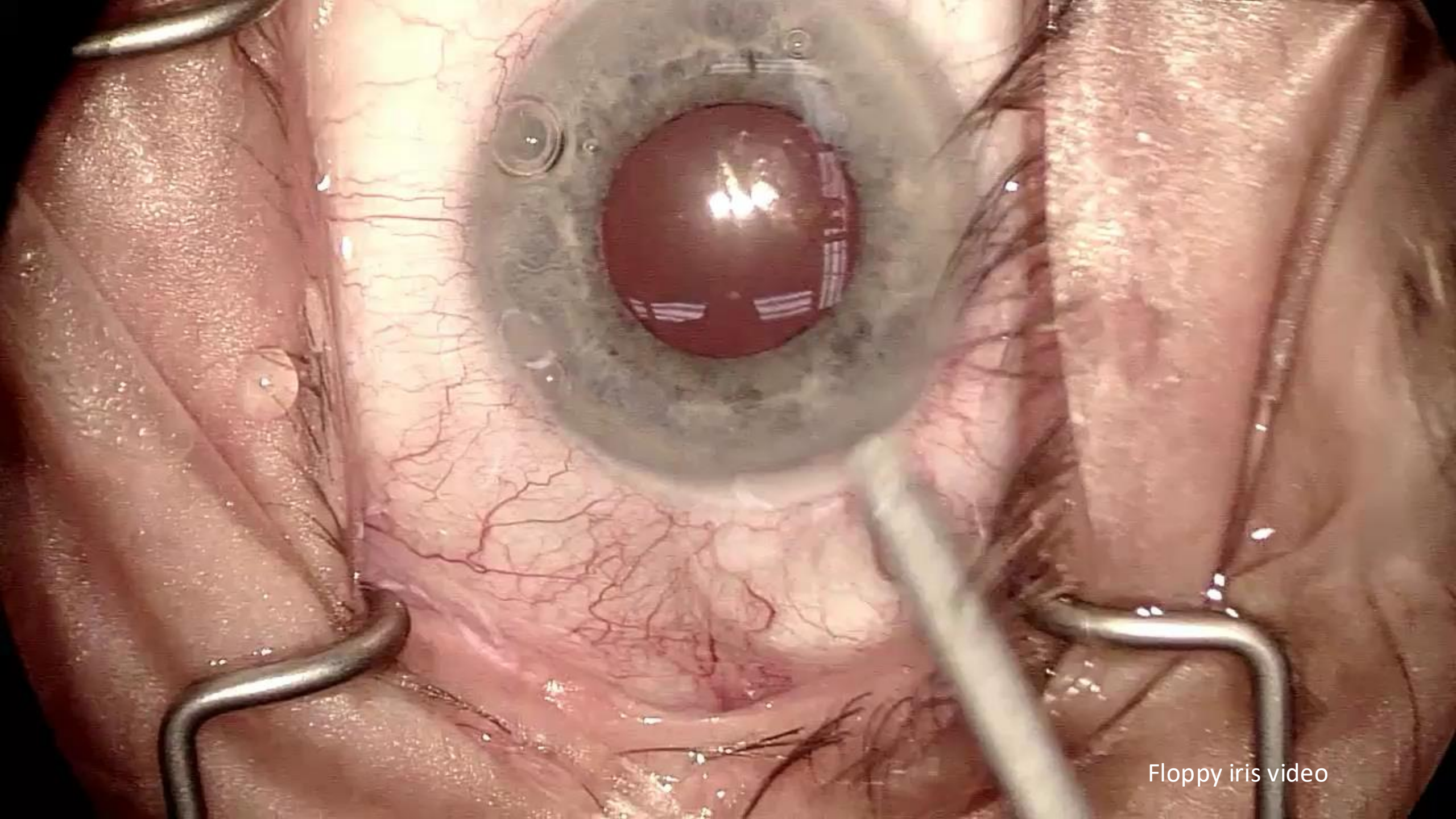
Iris Prolapse Into Incisions

Progressive Pupillary Miosis

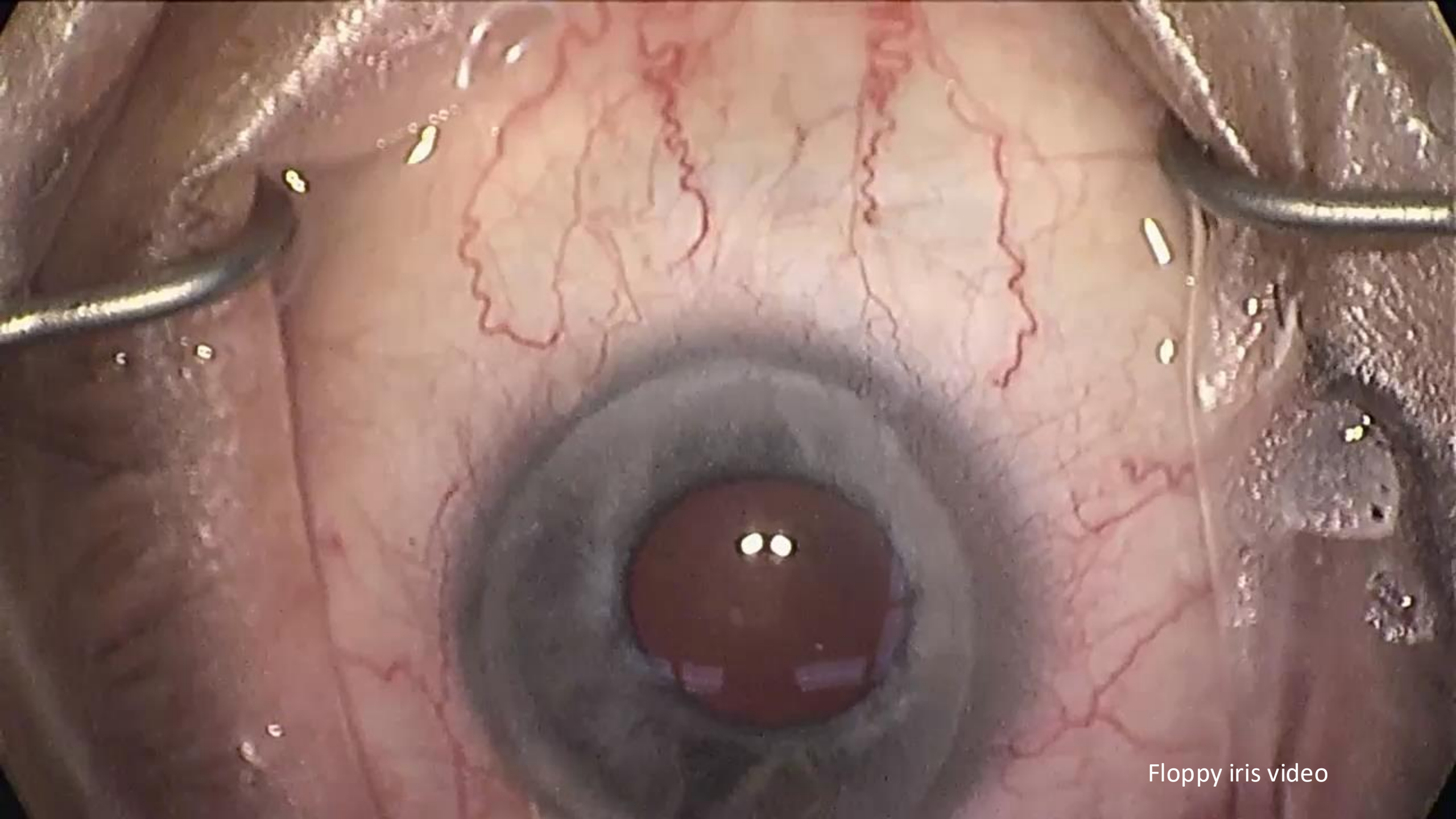




Floppy iris video



Floppy iris video



Floppy iris video

My Approach to Small Pupils

Identify them in clinic

Intracameral

Phenylephrine 1.5%/Lidocaine 1%

Phenylephrine 1.0%/ Ketorolac 0.3% in BSS

Viscodilation

Pupil Expansion Device



Associated Medication

Originally associated with current or prior use of tamsulosin (Flomax)

HTN and BPH

Doxazosin (Cardura), terazosin (Hytrin), prazosin (Minipress), labetalol (Trandate), alfuzosin (Uroxatral), silodosin (Rapaflo)

Antipsychotic agents

Chlorpromazine (Thorazine)

Other drugs and supplements with α -adrenergic antagonist activity



Loose Zonules

- Pseudoexfoliation
 - Trauma
 - Coloboma
 - Congenital (Marfan's etc)
 - Aniridia
 - Chronic Uveitis
 - RP
 - Surgical Trauma
-



In the Clinic

- Pupil Size and Shape
- Asymmetry of AC Depth
- Subtle Phacodonesis
- Iris transillumination defects

- Iridodialysis
- Gonioscopy



In the OR

- Look for wrinkling of the capsule
- Round, large capsulorhexis
- Good Hydrodissection
- Hydrodilatation
- Low flow phaco settings
- Avoid chamber shallowing
- Chop/Stop & Chop/Horizontal Phaco
- Tangential stripping of cortex
- Be ready for CTR/CTS/Capsular hooks
- IOL Selection



Rotation Issues

courtesy Alan Crandall

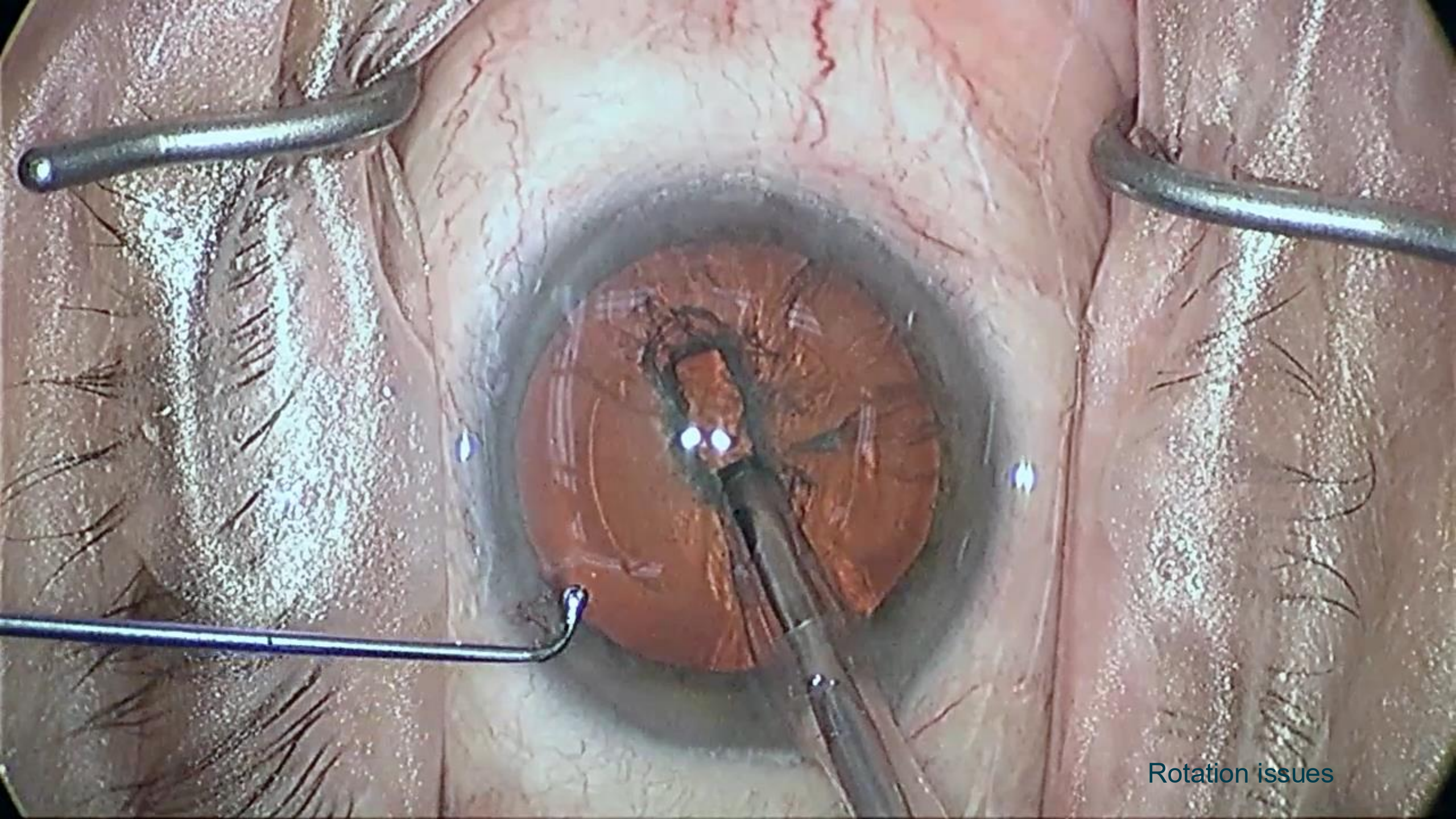


Irrigation and Aspiration

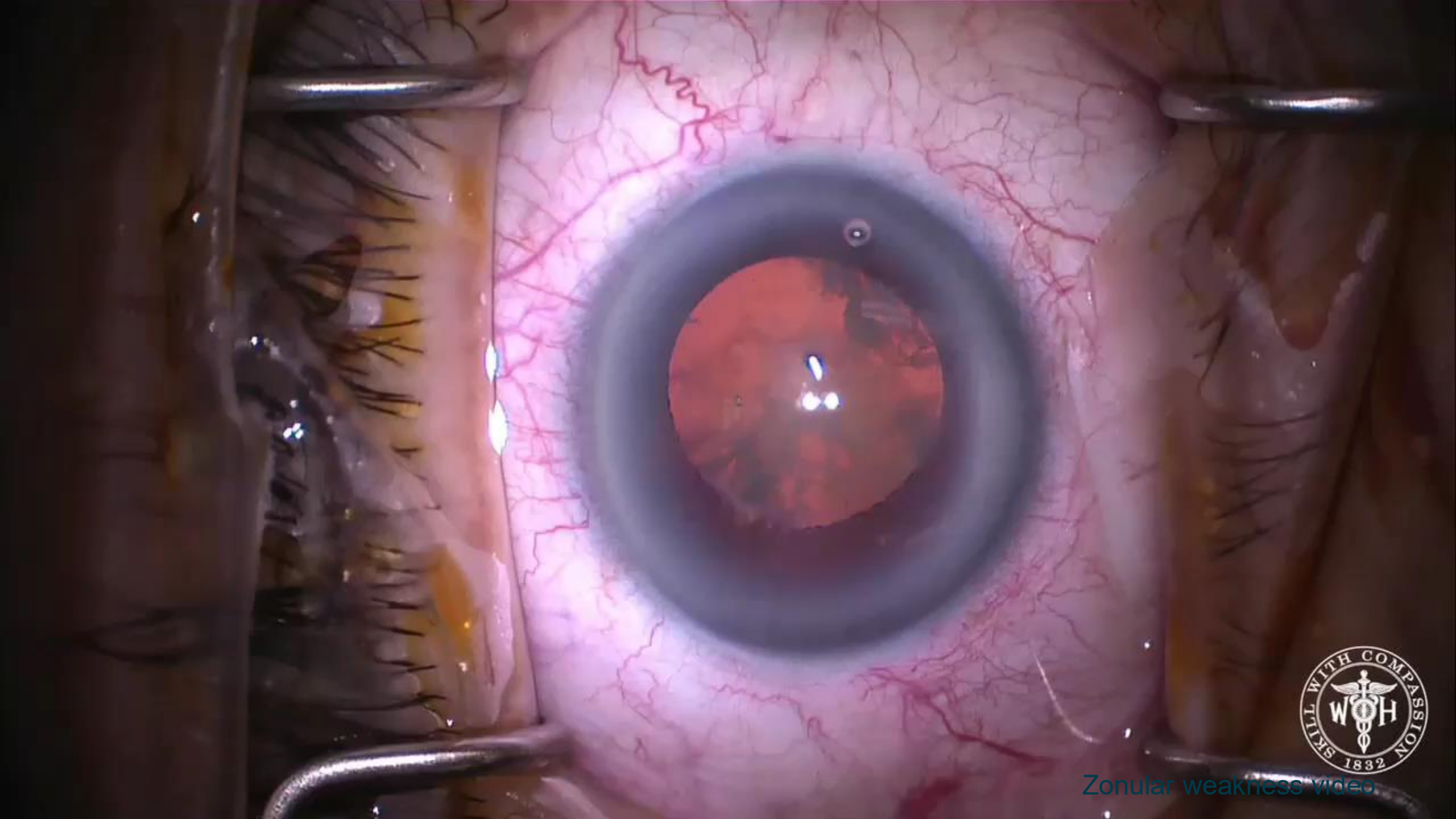
Radial versus Tangential

Celso Takashi and Liliana Werner courtesy Alan Crandall



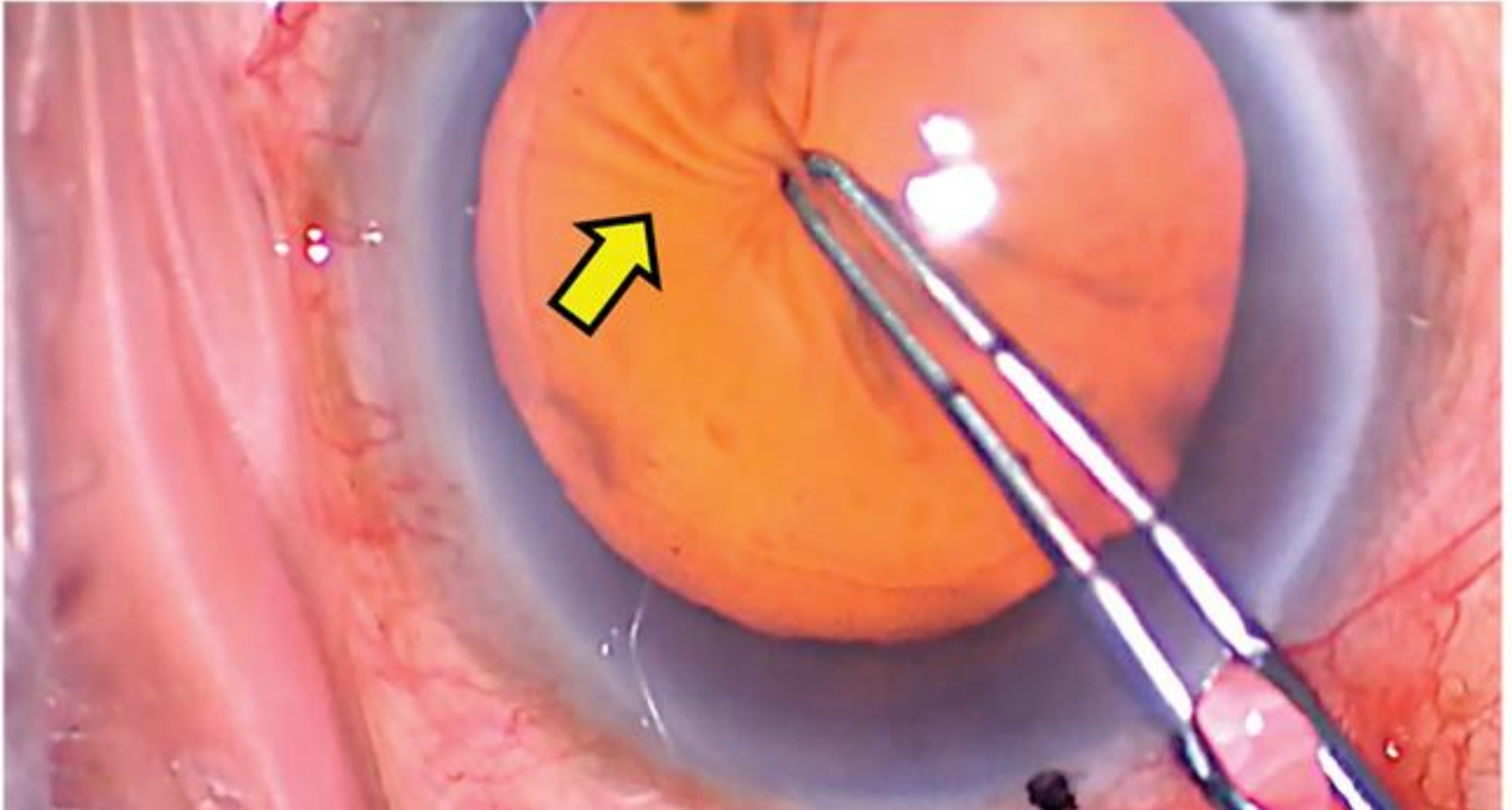


Rotation issues

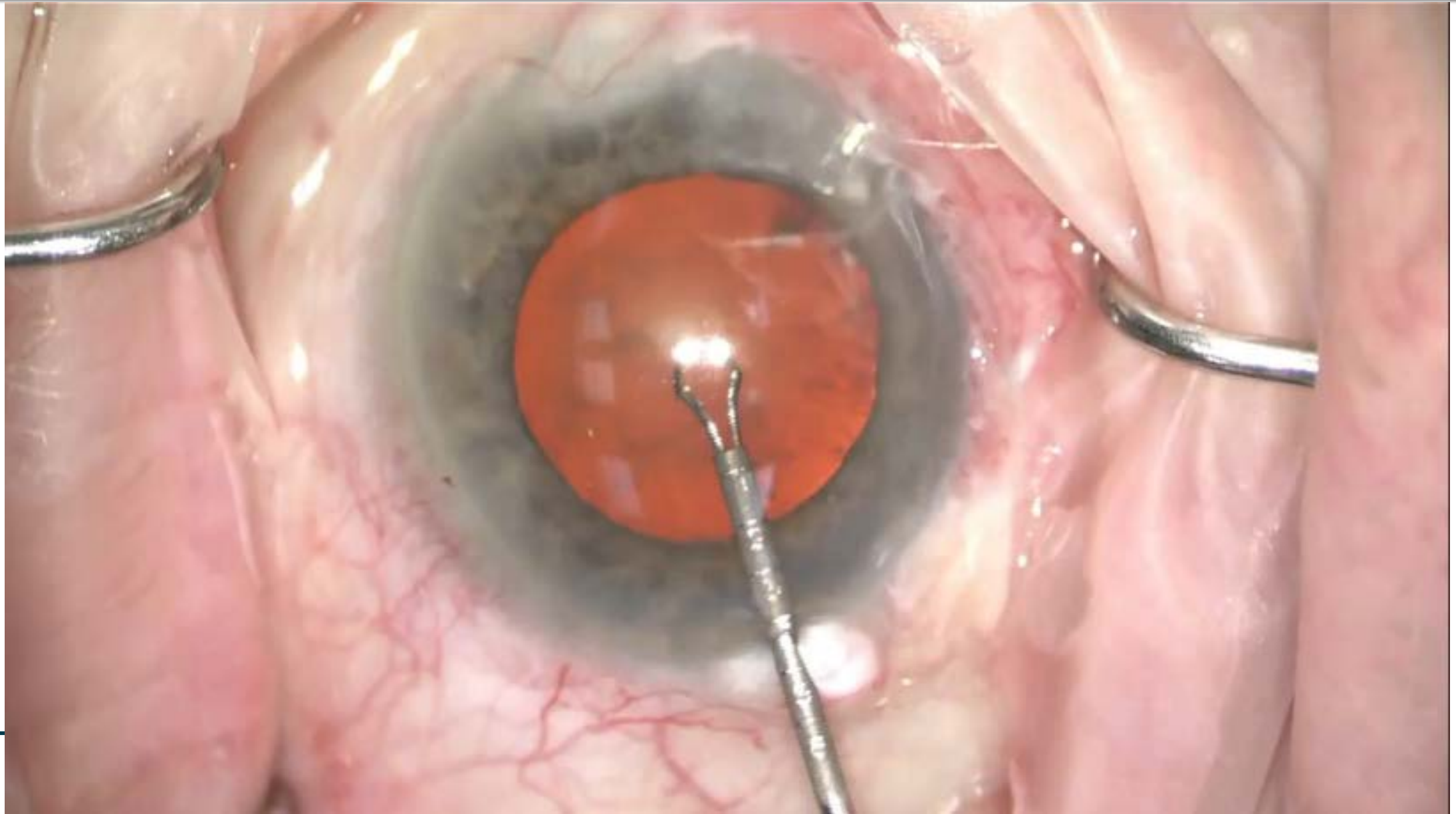


Zonular weakness video

Be alert for capsule wrinkling



Be alert for capsule wrinkling





Perform rotation carefully

Remove cortex tangentially,
NOT radially

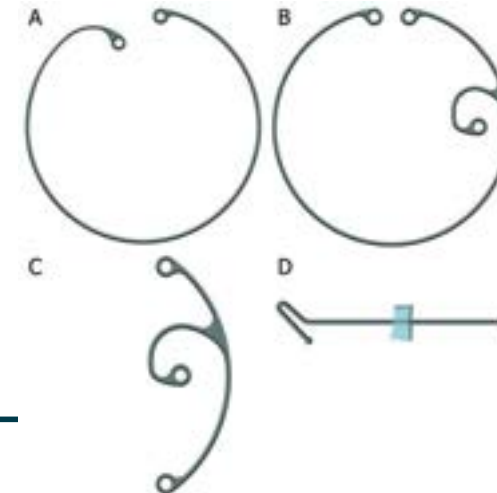
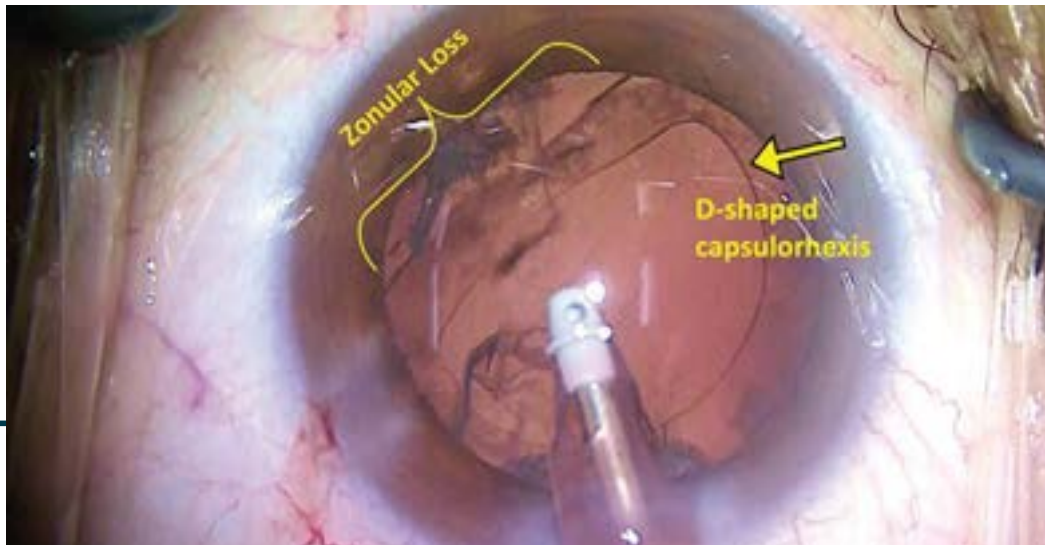
Remove lens epithelial cells
(LEC)

Be prepared to support the capsule


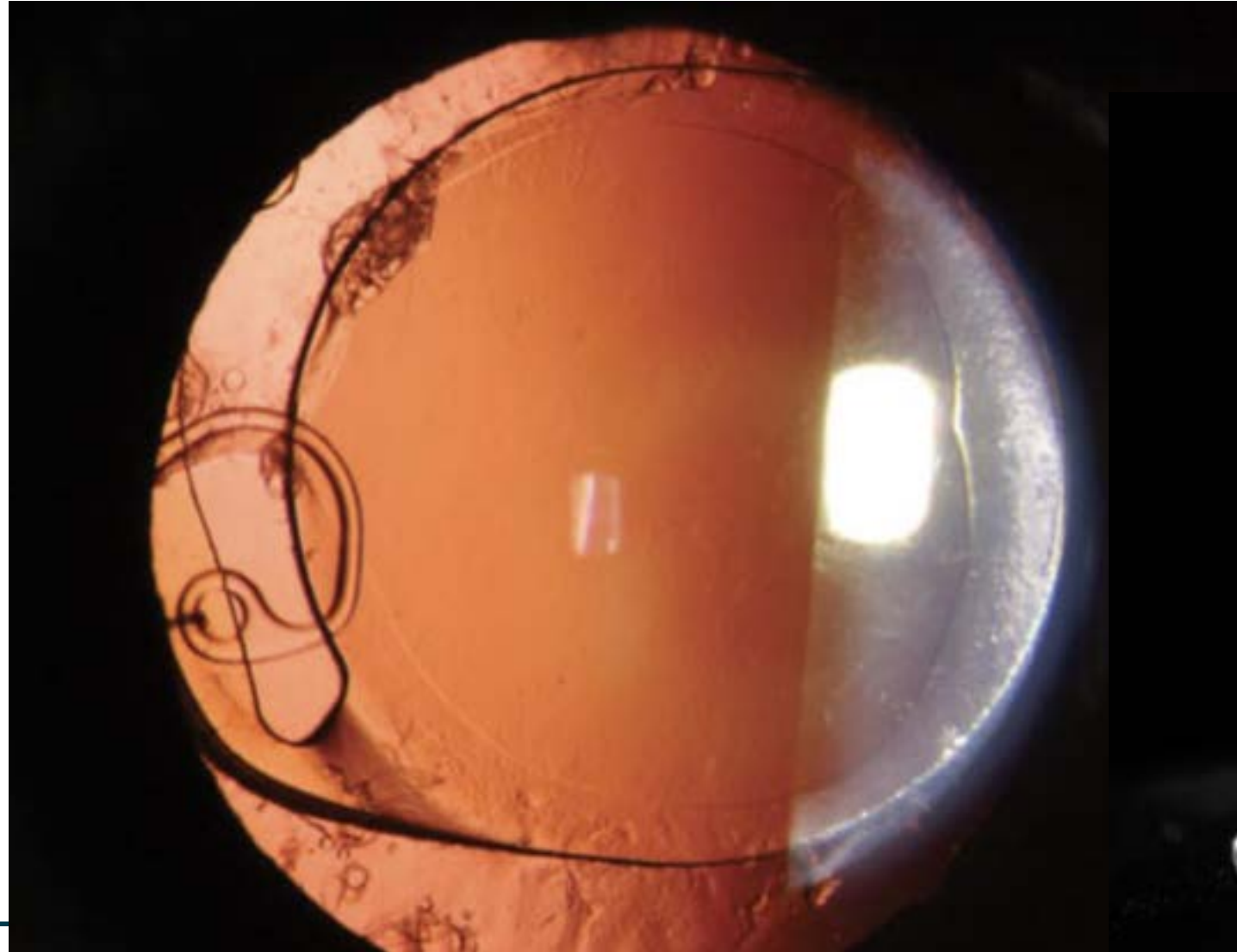
- Anticipate zonular dialysis 2 clock hrs larger than clinical appearance
- Zonulopathy Grading
 - Mild: <3 clock hrs
 - Moderate: 3-6 clock hrs
CTR
 - Severe: >6 clock hrs
sacrifice

CTR
Mod- CTR or CTS +

CTSx2 + CTR vs



Capsule Tension Segment (CTS)



Loose zonules case

<https://youtu.be/29aWbd15Nwc>




Plan A and B for IOL Placement



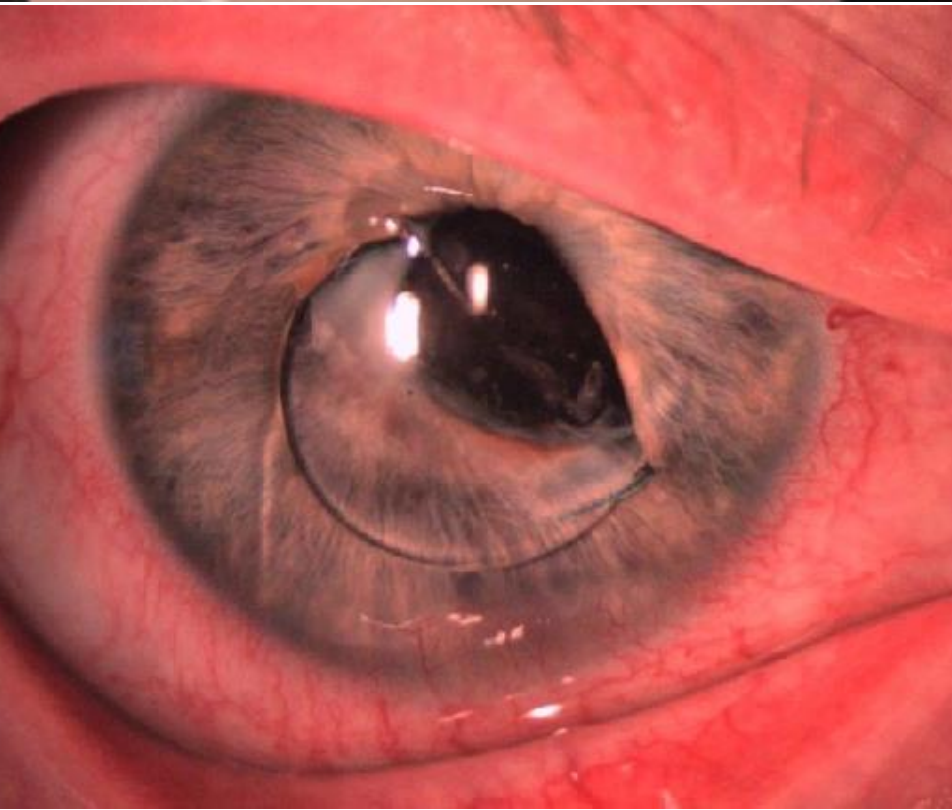
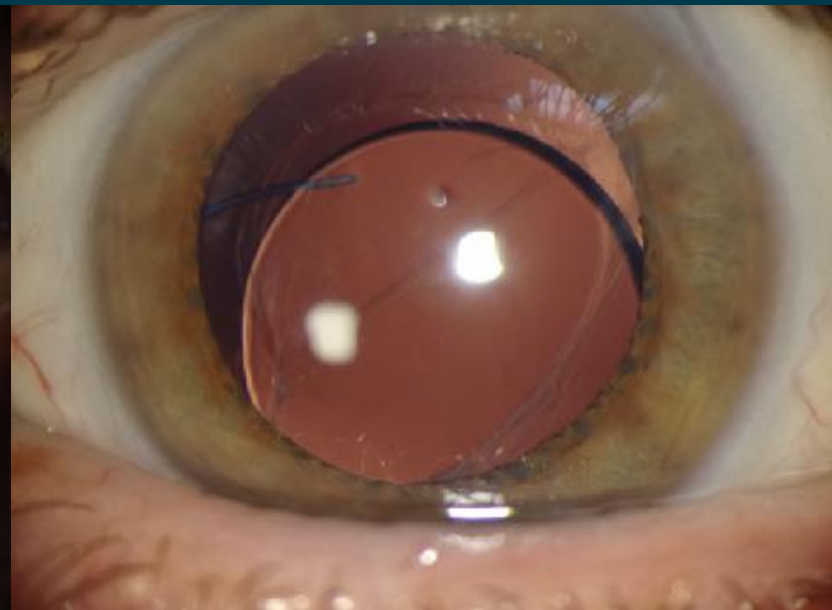
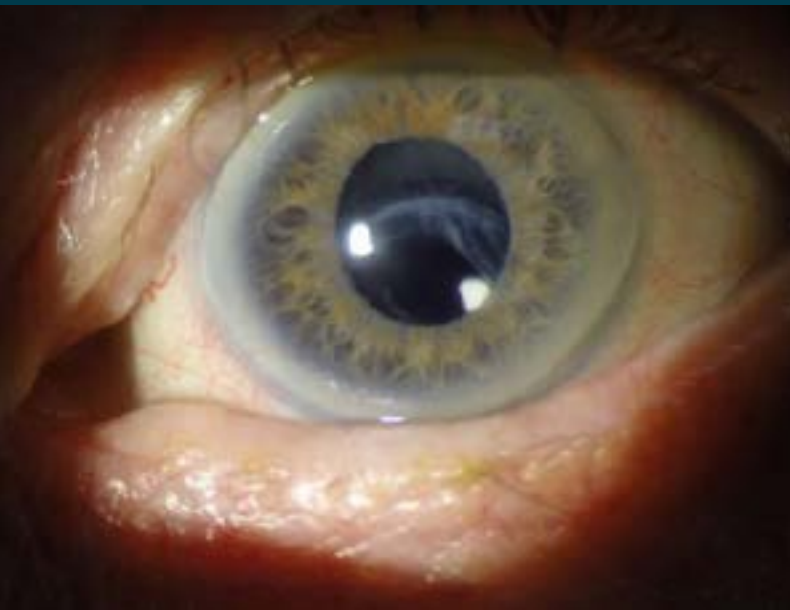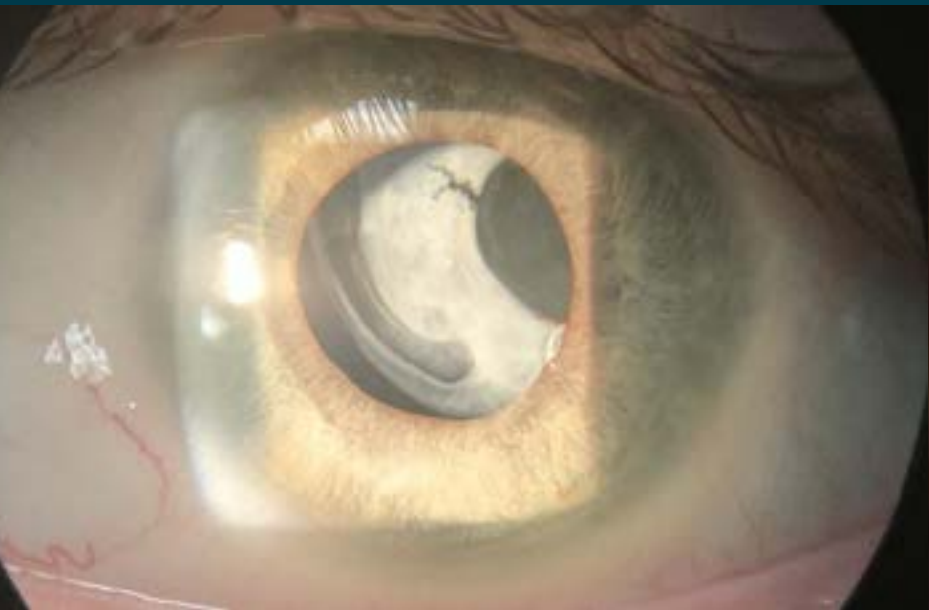Placement:

BAG ONLY

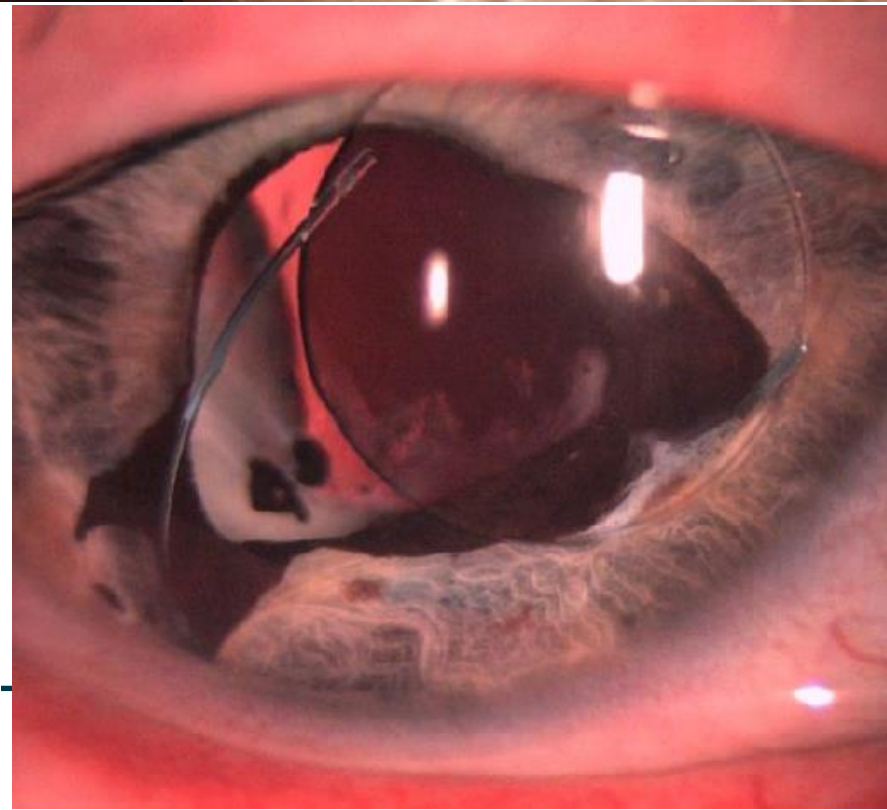


Placement:

BAG/SULCUS/FIXATE



COMPLEX CASES



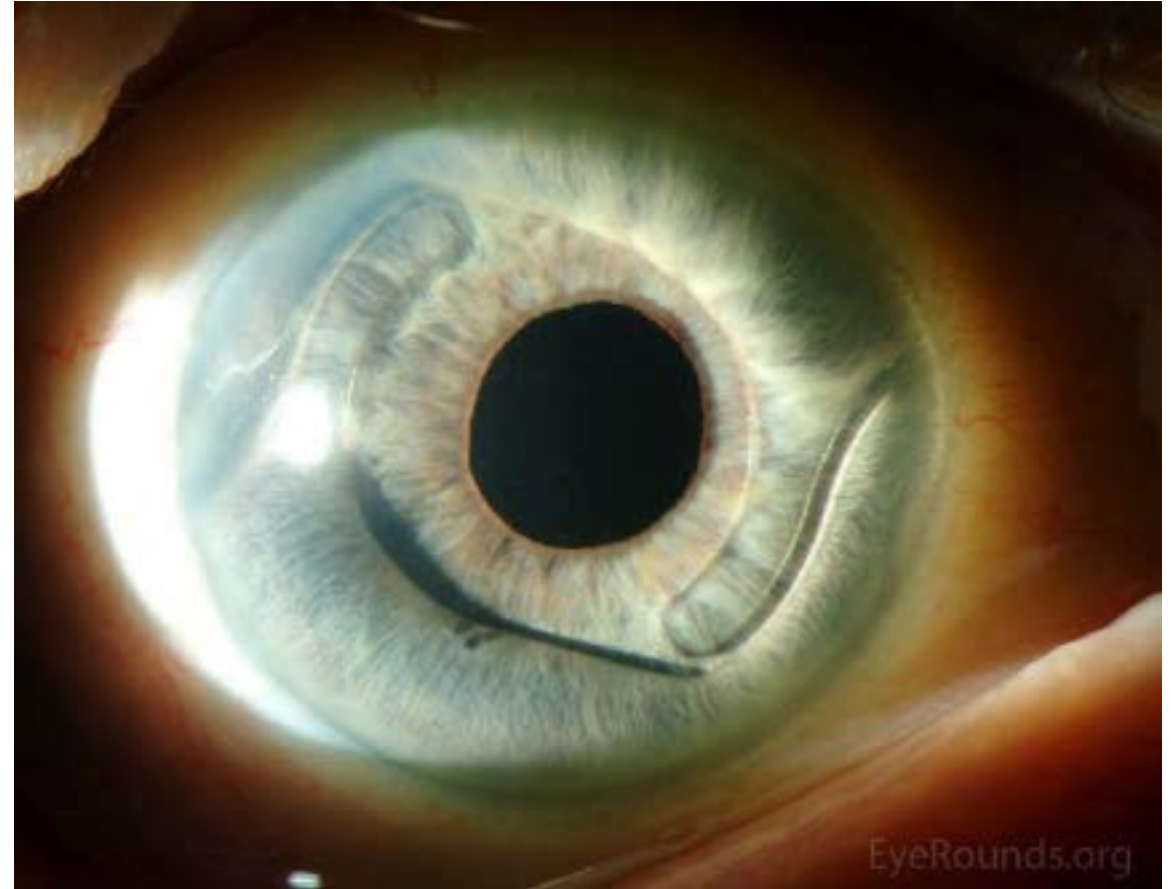
AC IOLs

Advantages:

- Fast
- Technically simpler

Disadvantages:

- Glaucoma
- Corneal decompensation
- Large incision
- Sizing difficulty



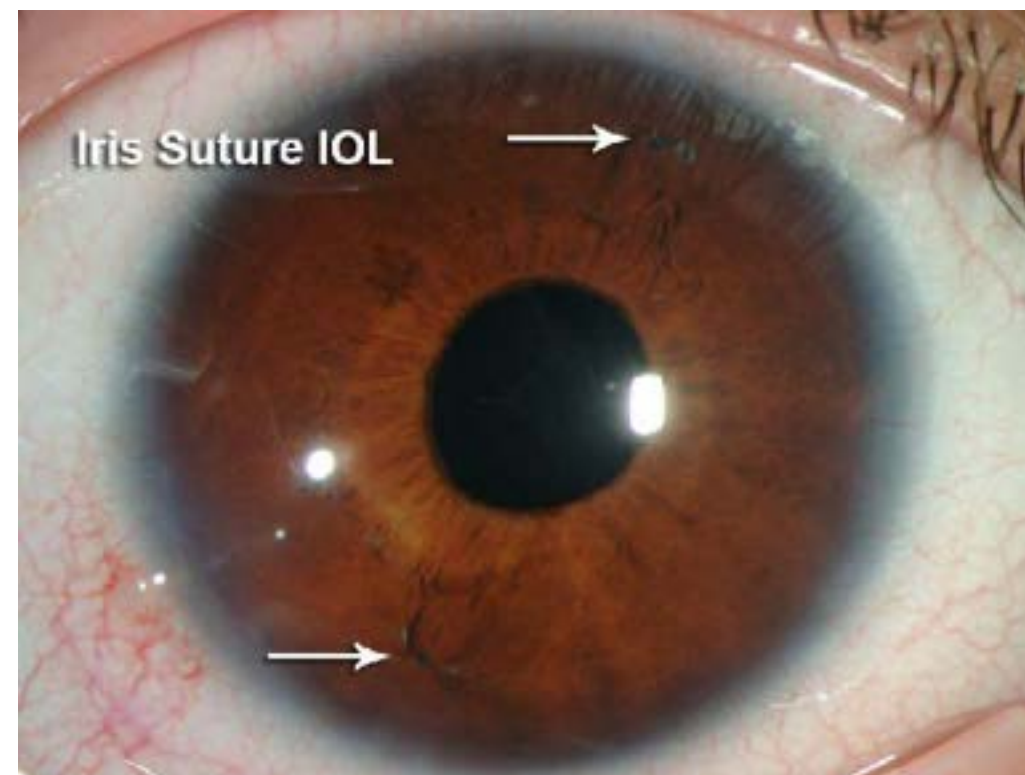
Iris Fixated IOL

Advantages:

- Small incision
- Elegant, no external sutures

Disadvantages:

- Technically challenging
- Iris chafe/UHG
- Pupil irregularity



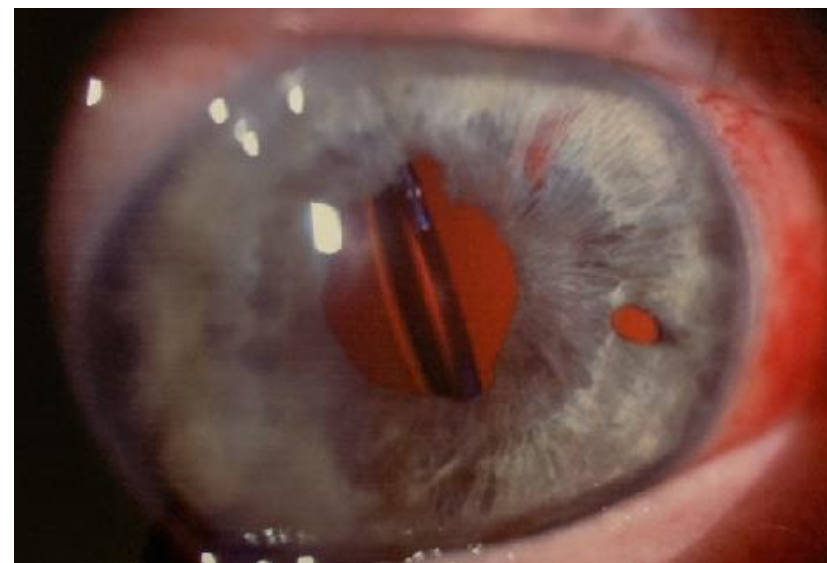
Sclera Fixated IOL

Advantages:

- Anatomic location
- Can be small incision
- Stability

Disadvantages:

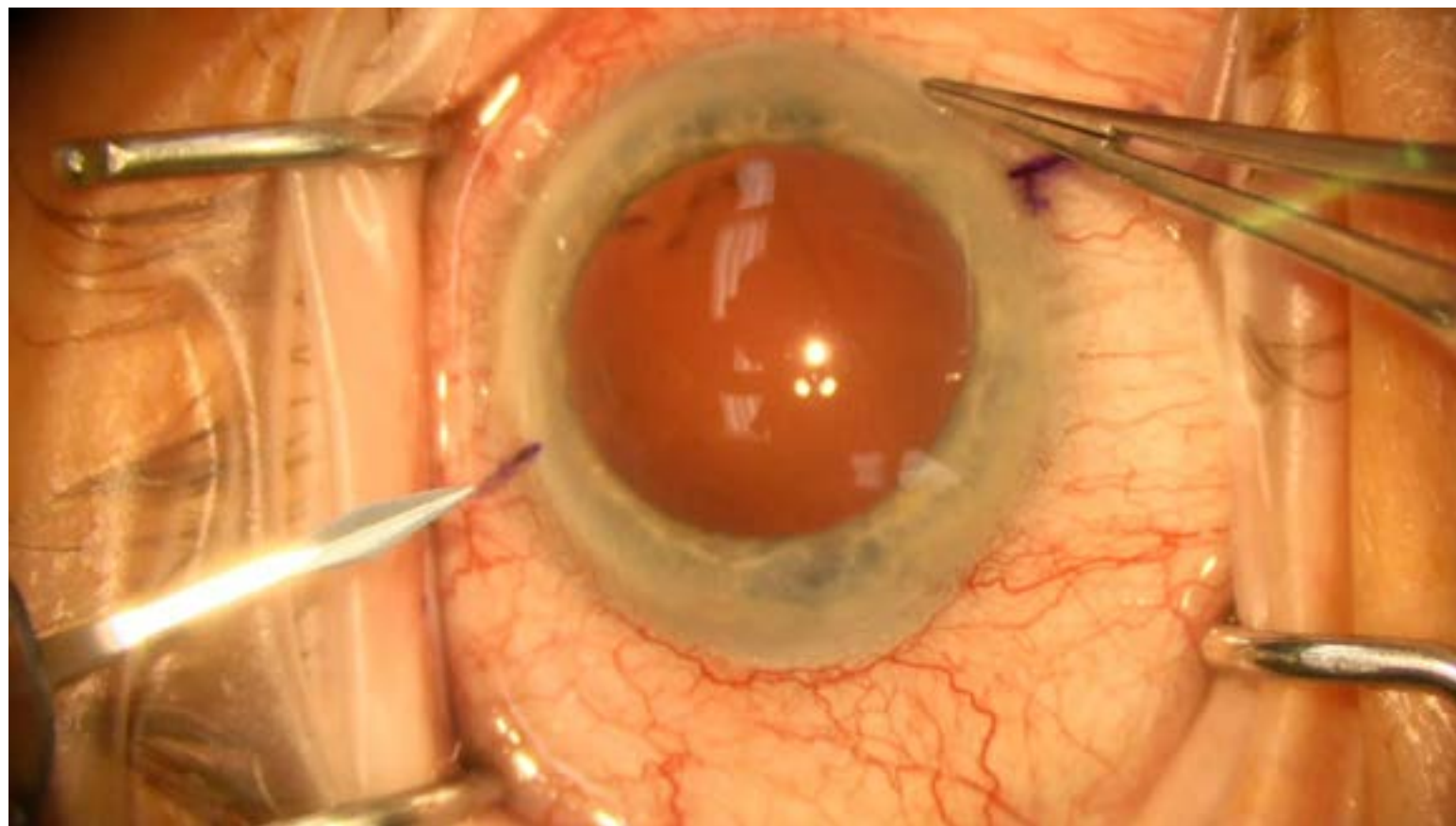
- Time and difficulty
- Late dislocation
- Lens tilt or rotisserie



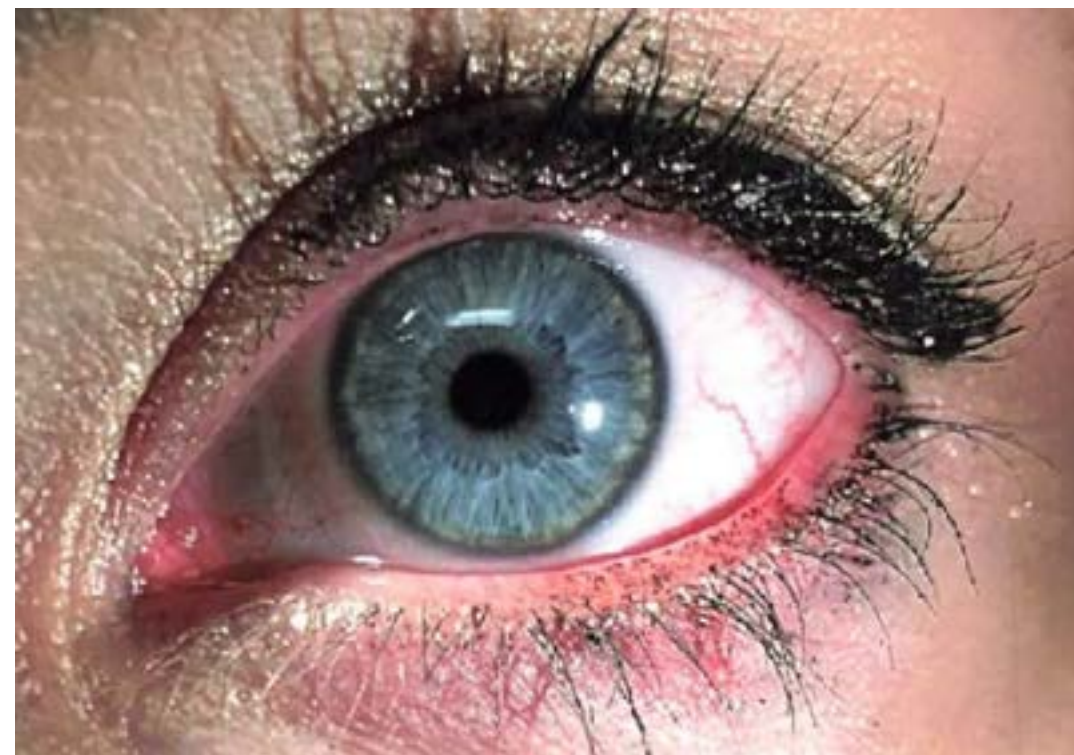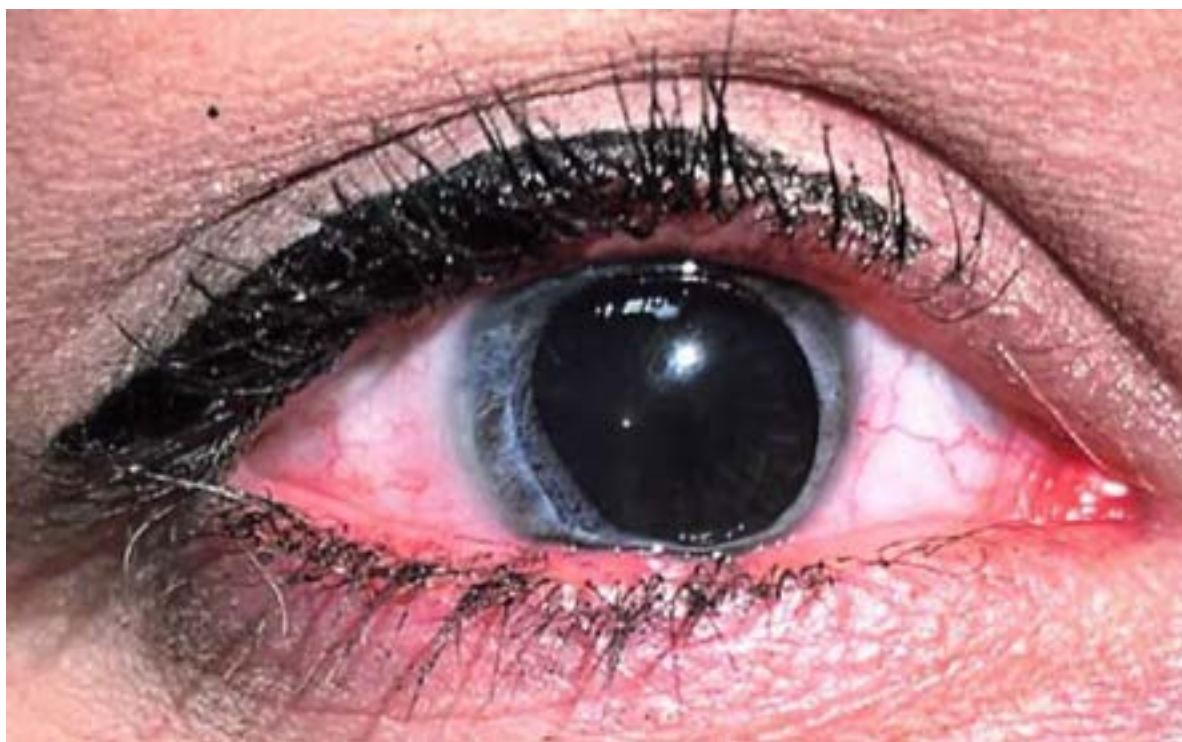
Dislocated IOLs and Aphakia

Have plan A, plan B and potentially plan C

- Iris fixate
- Lasso
- Yamane
- Scleral fixate
- AC IOL



Case

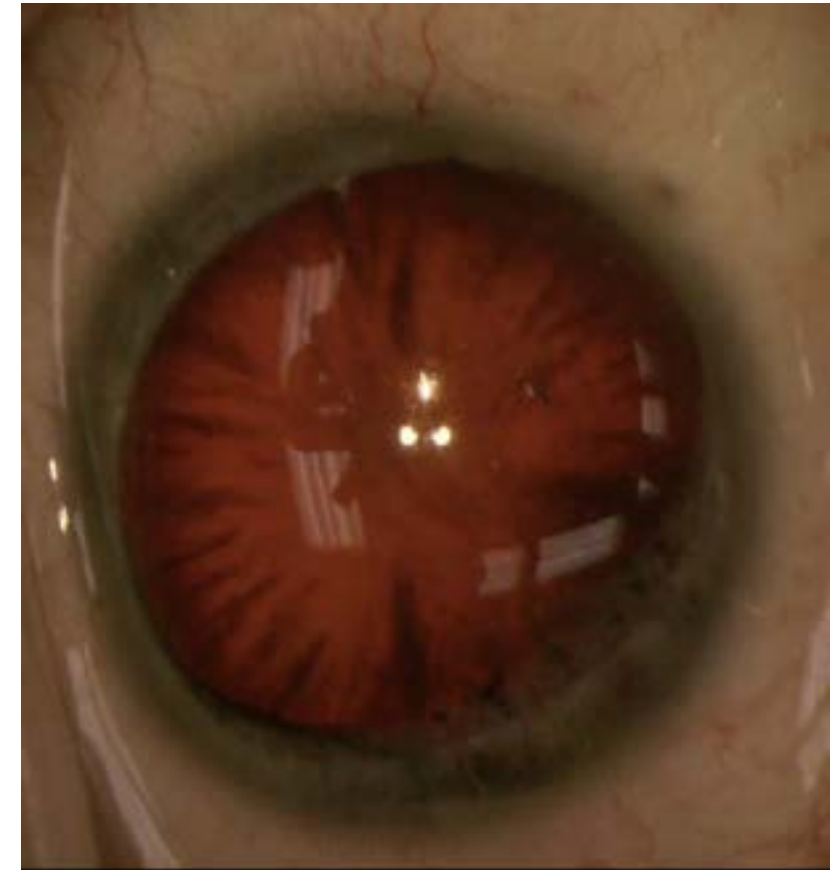

COMPLEX CASES



Exam

- VA: OD: 20/25 OS: 20/20
- BAT: OD: 20/100 OS: 20/20
- IOP: OD: 16 OS: 15
- Pupils: No RAPD by reverse; anisocoria
- SLE:
 - Cornea: clear OU
 - Iris: atrophic iris tissue with mydriasis OD, normal OS
 - AC: Deep and quiet OU
 - Lens: OD: 1+ NS 2-3+ CC OS: clear
 - Gonio: OD: 3-4+ TM pigment, open to CB OS: 1-2+ pigment open to CB



Traumatic Aniridia

Traumatic Mydriasis

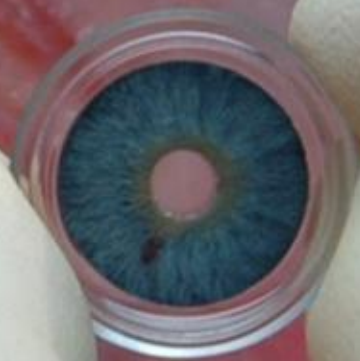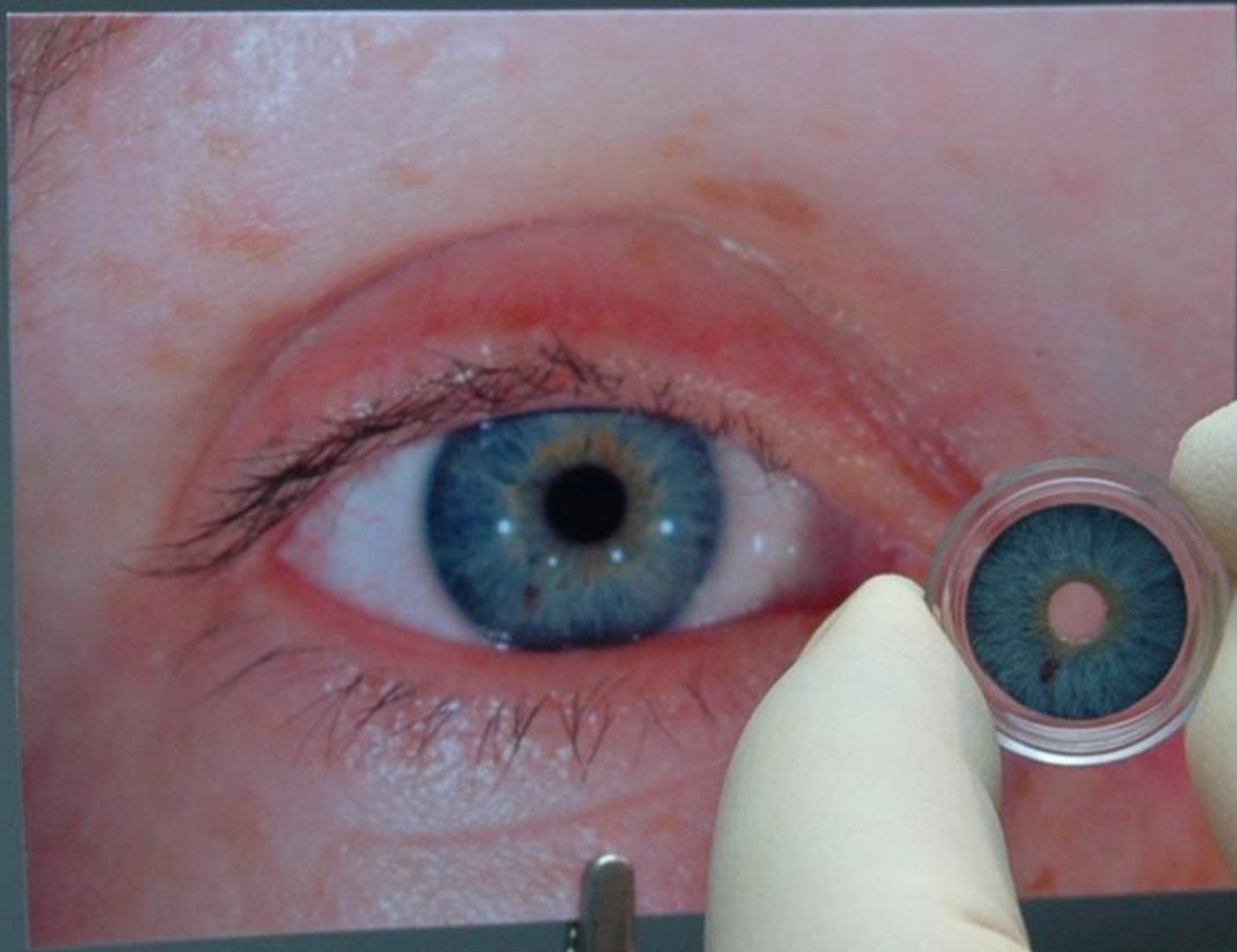
- Onset following trauma
 - Open globe
 - Surgical trauma
 - Floppy iris syndrome
- Can have extreme photophobia even with sunglasses inside
- Can be debilitating

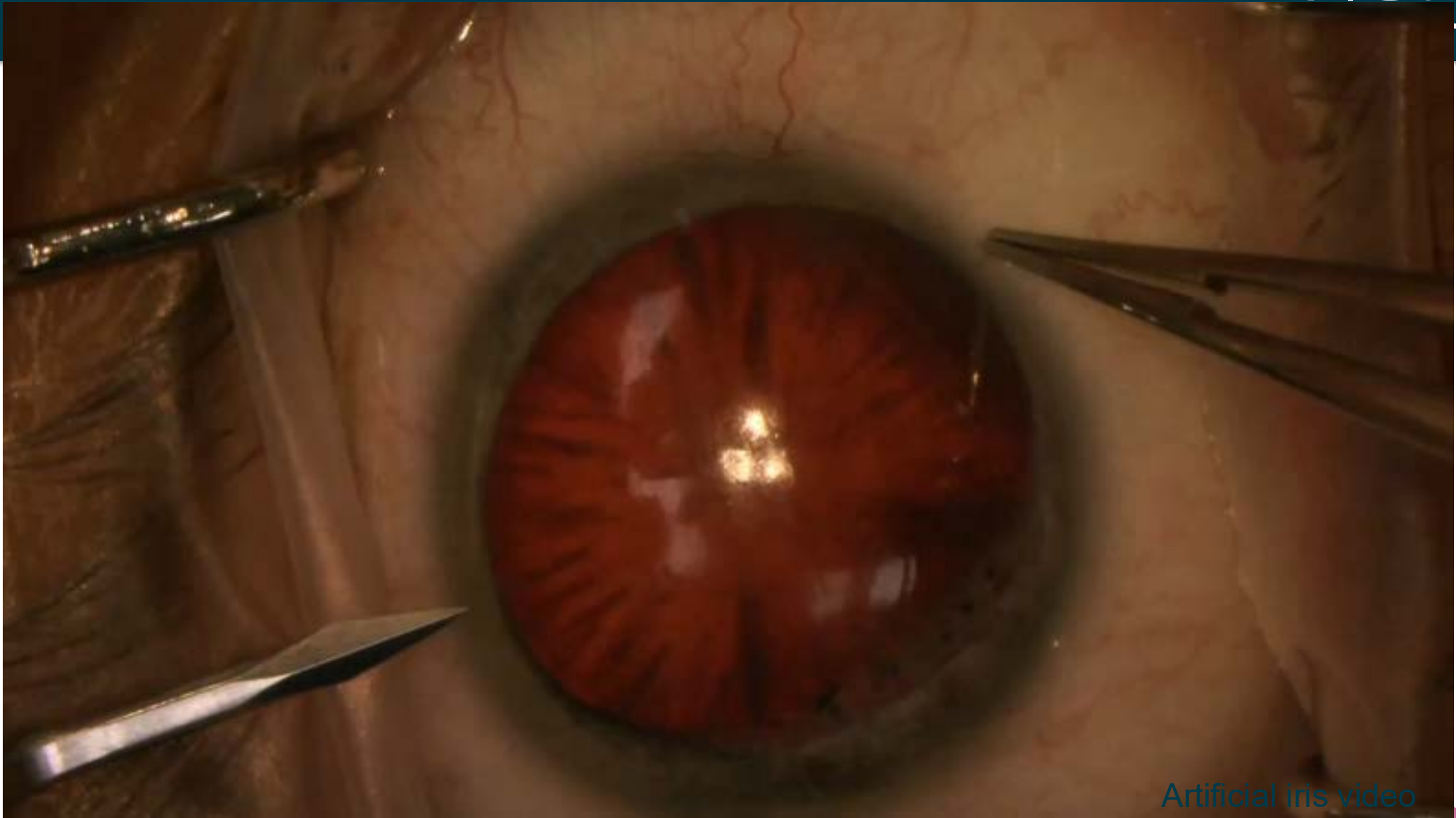


Repairing Traumatic Mydriasis

- Colored Contact Lens
- Corneal Tattoo
- Pupilloplasty
- Artificial Iris







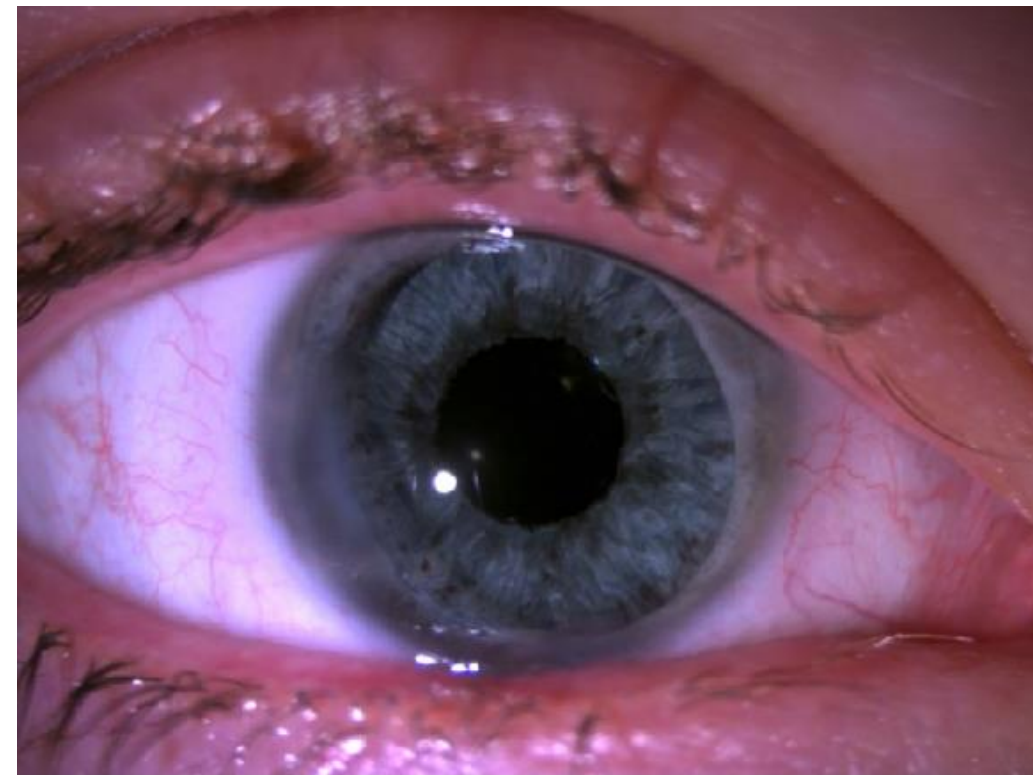
Artificial iris video

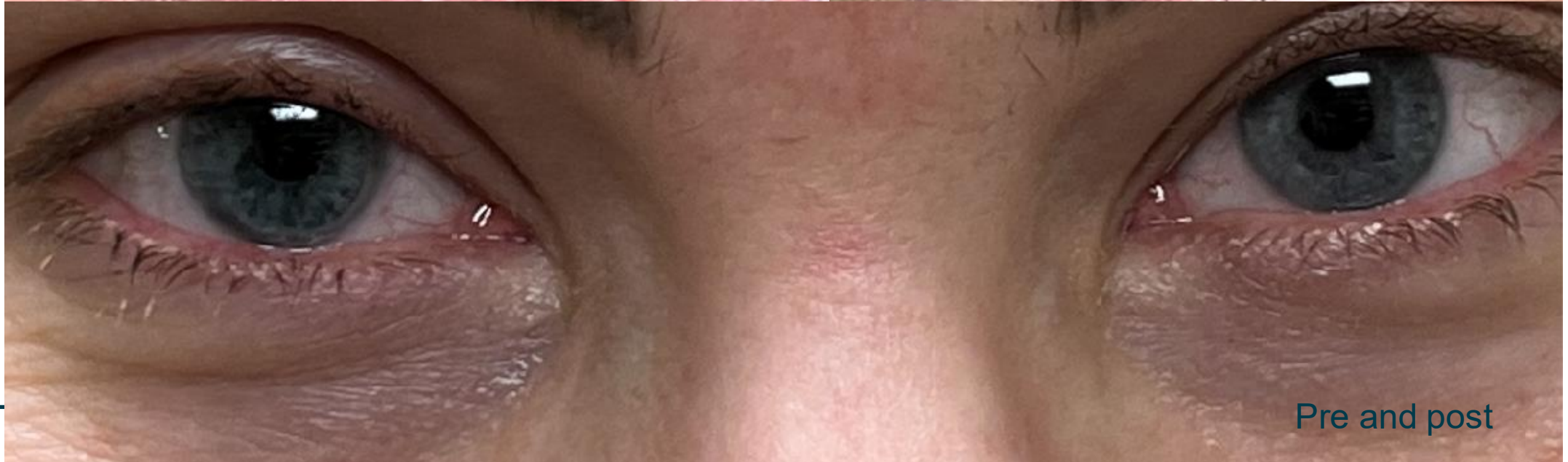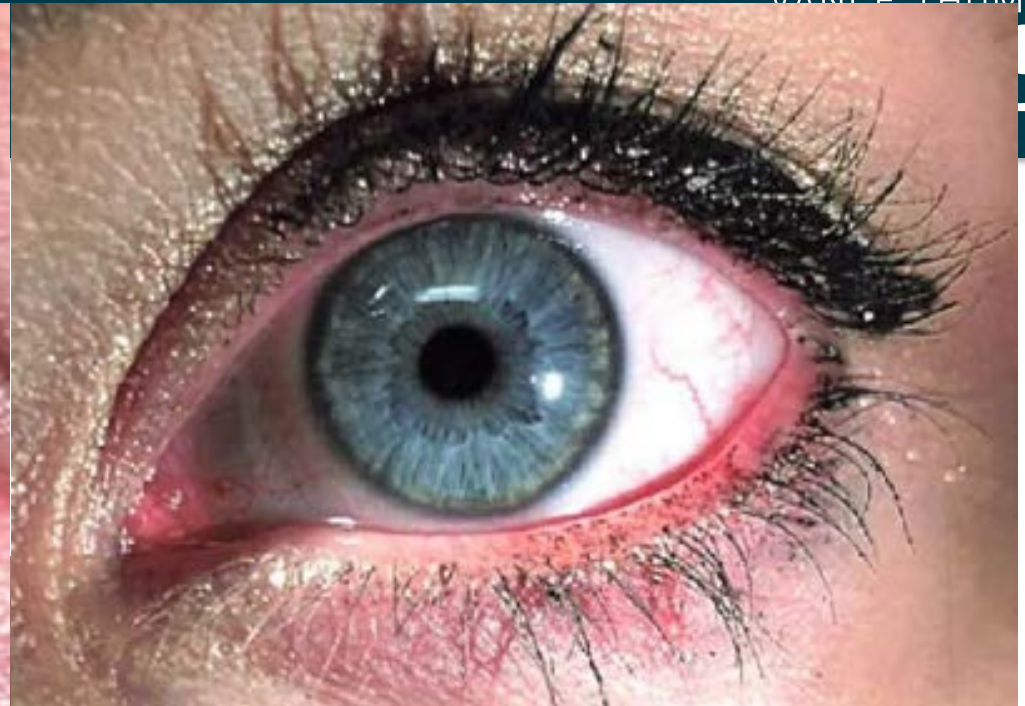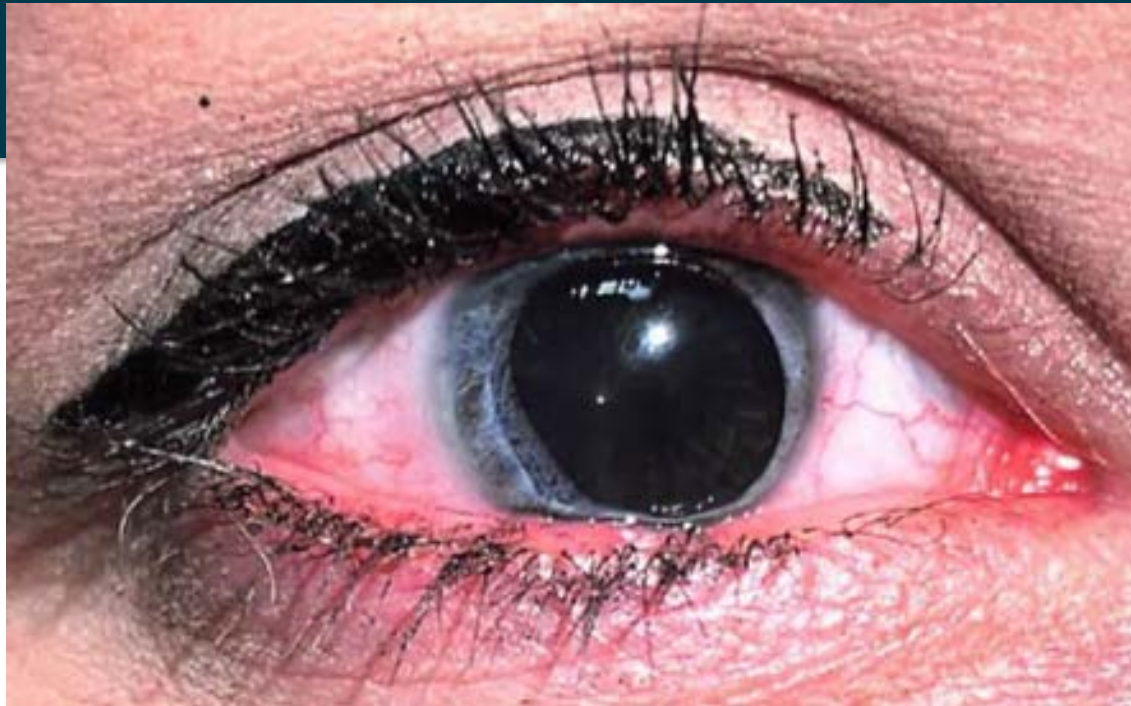
COMPLEX CASES



Post op 1 month

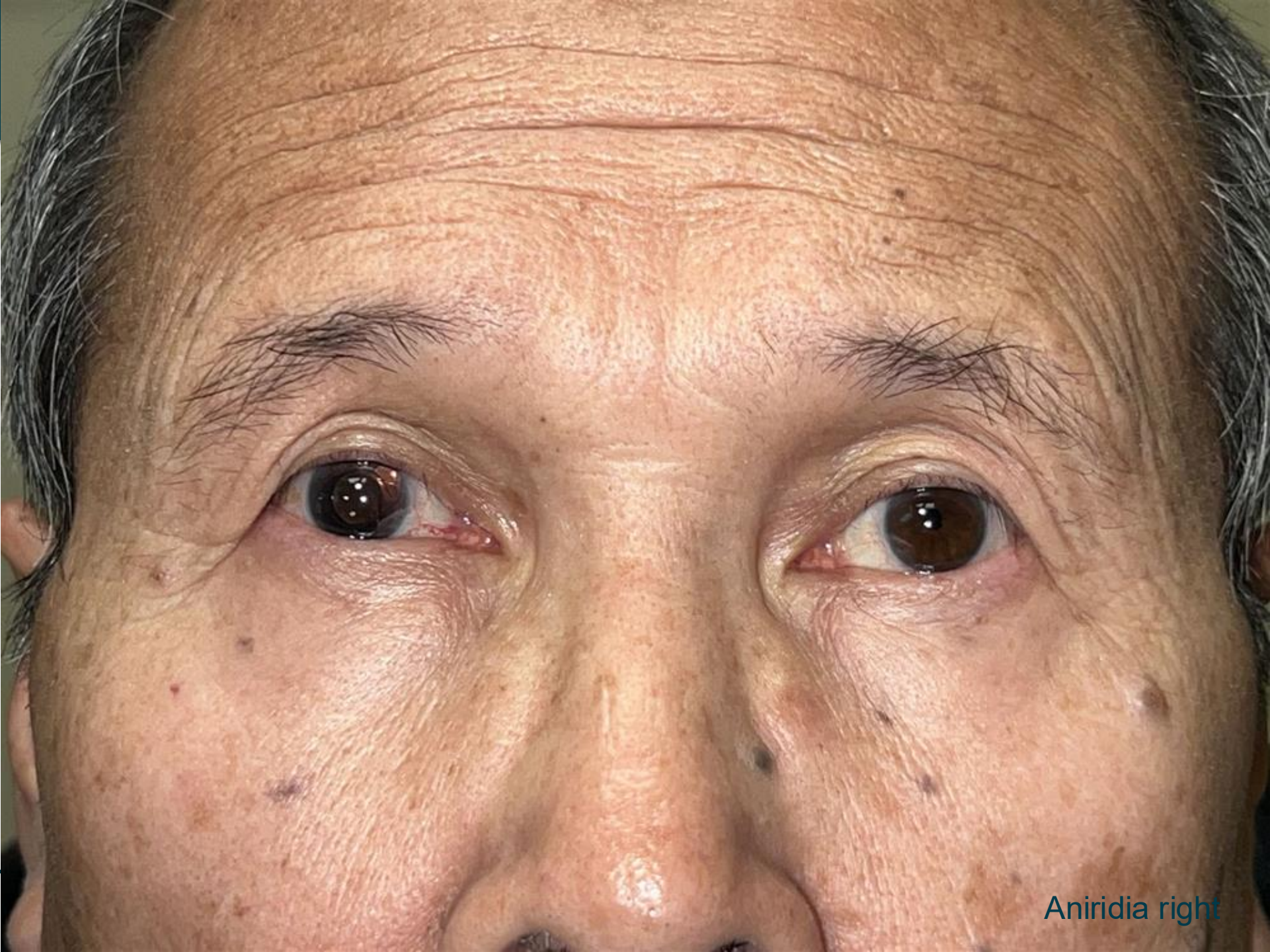- VA sc:
OD: 20/25+2
OS: 20/20
- Resolution of night time glare
- Patient very satisfied with cosmetic result as well





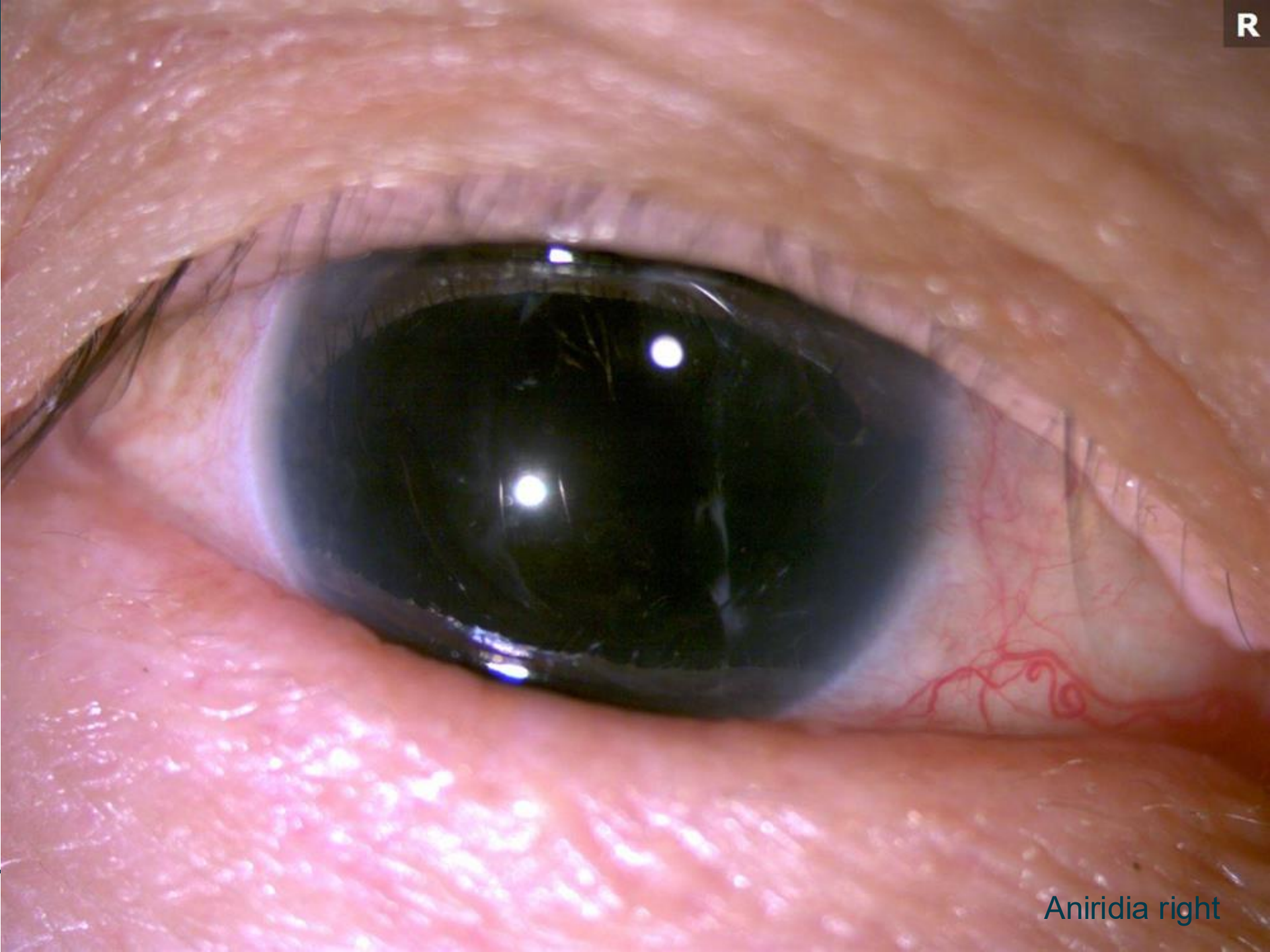Pre and post





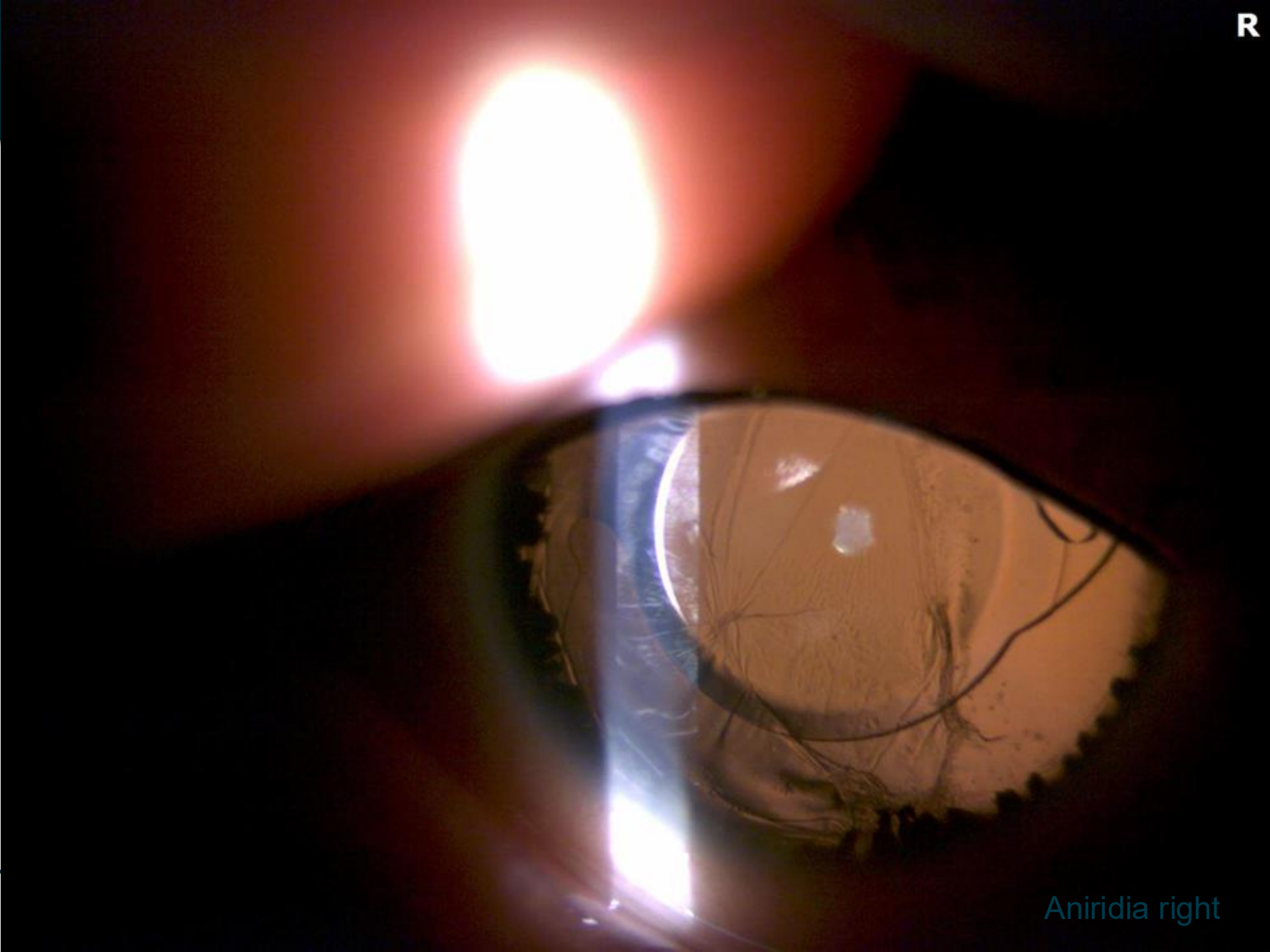
Aniridia right





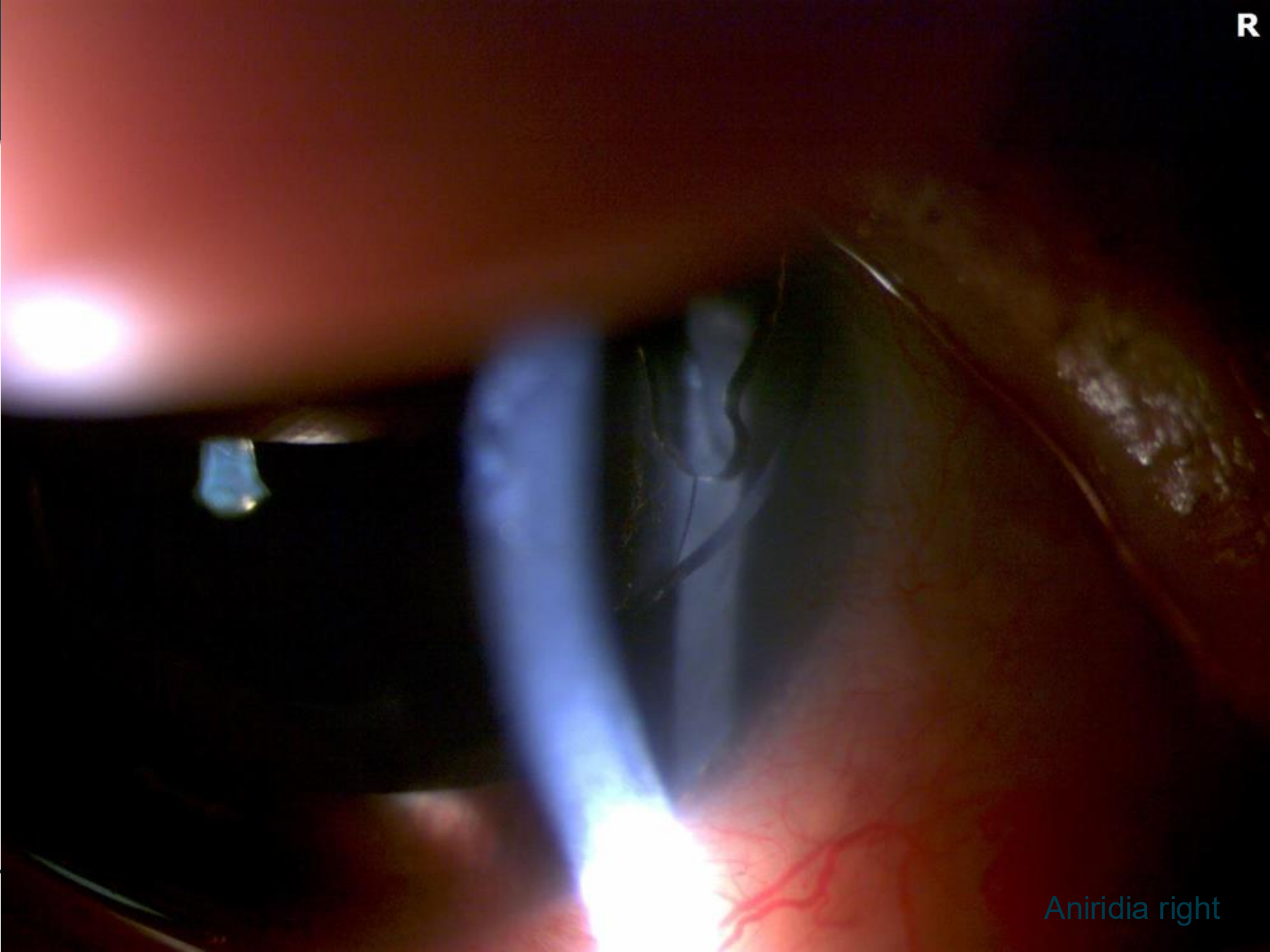
Aniridia right





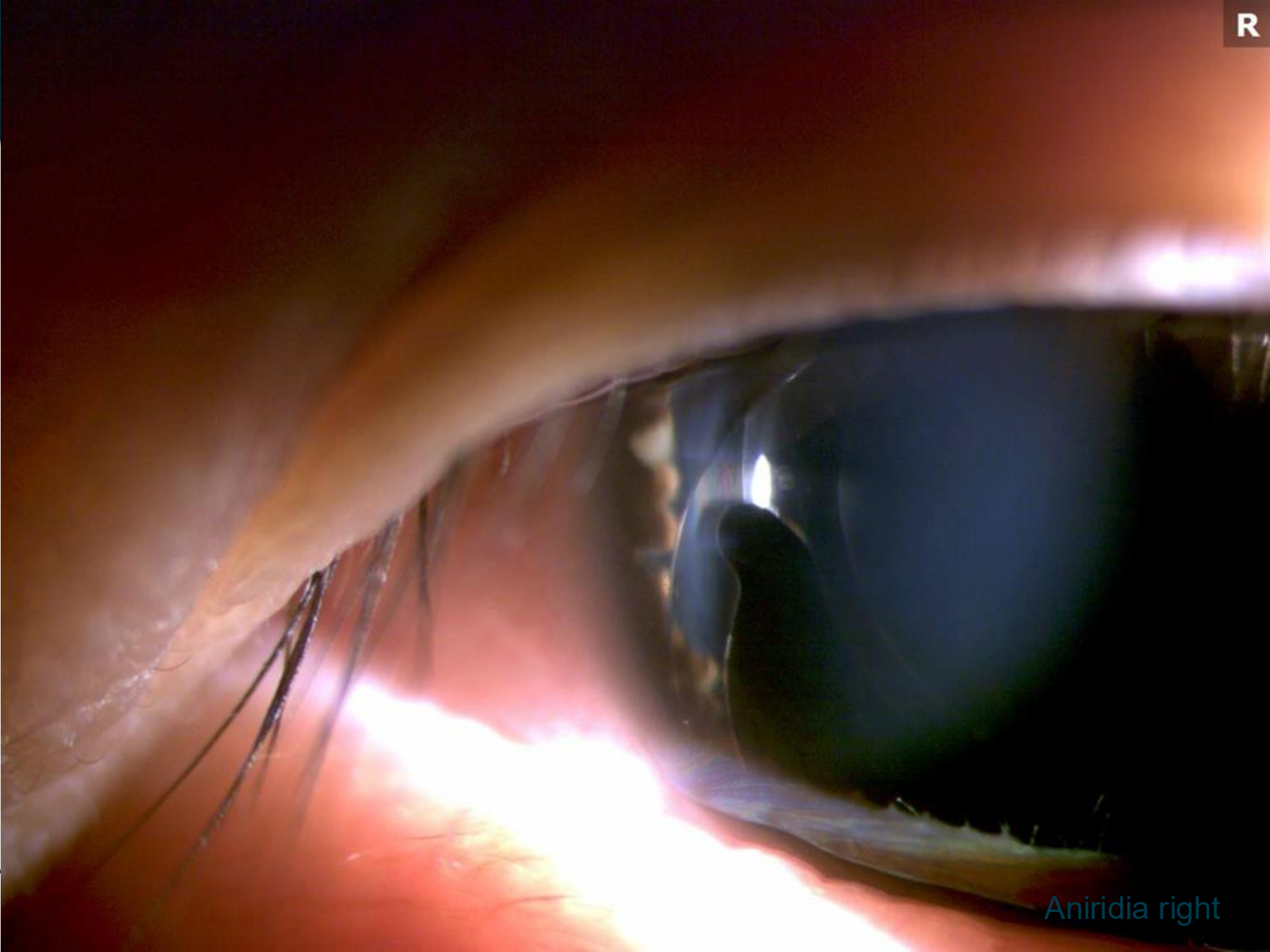Aniridia right





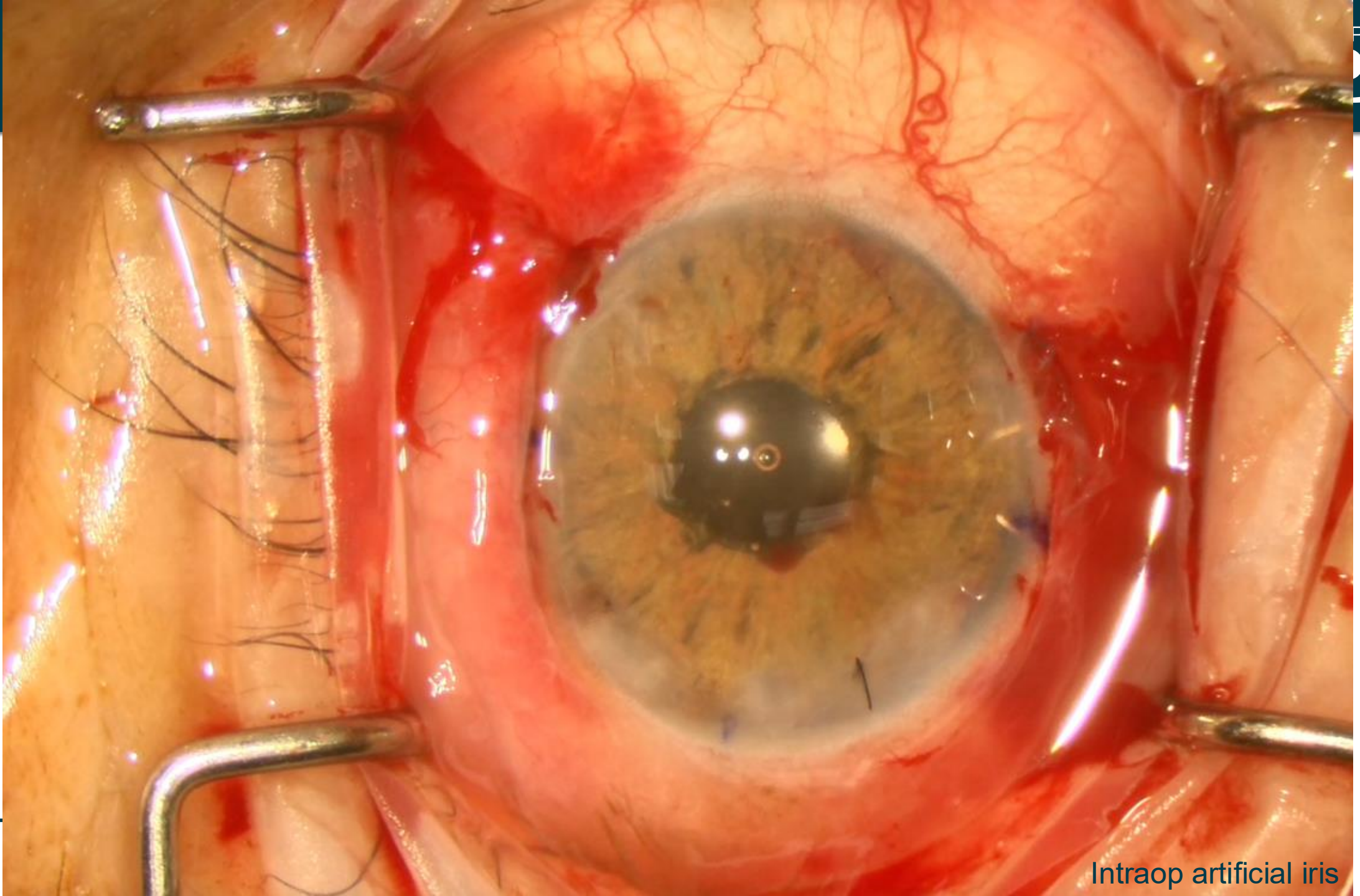
Aniridia right





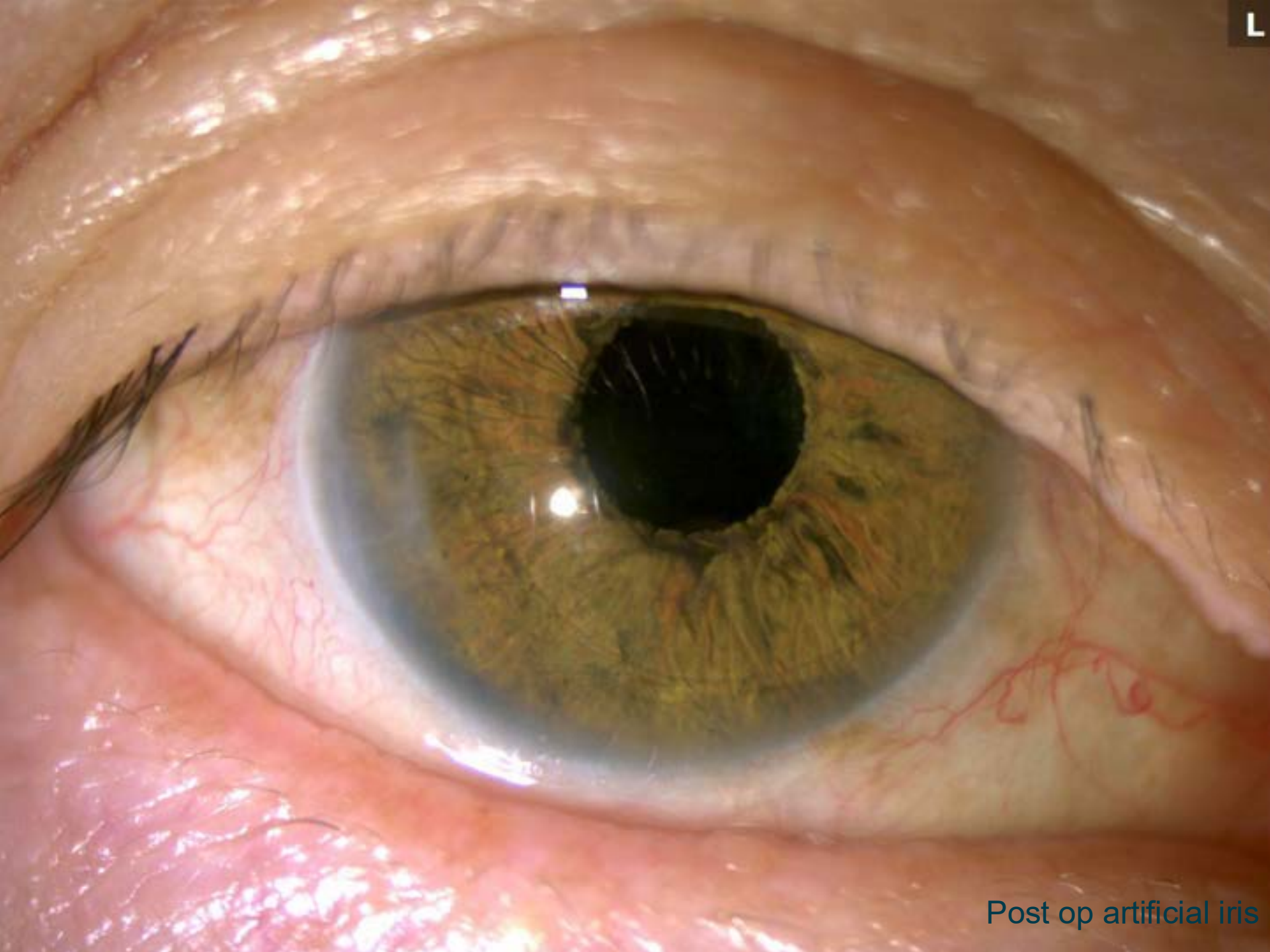
Aniridia right





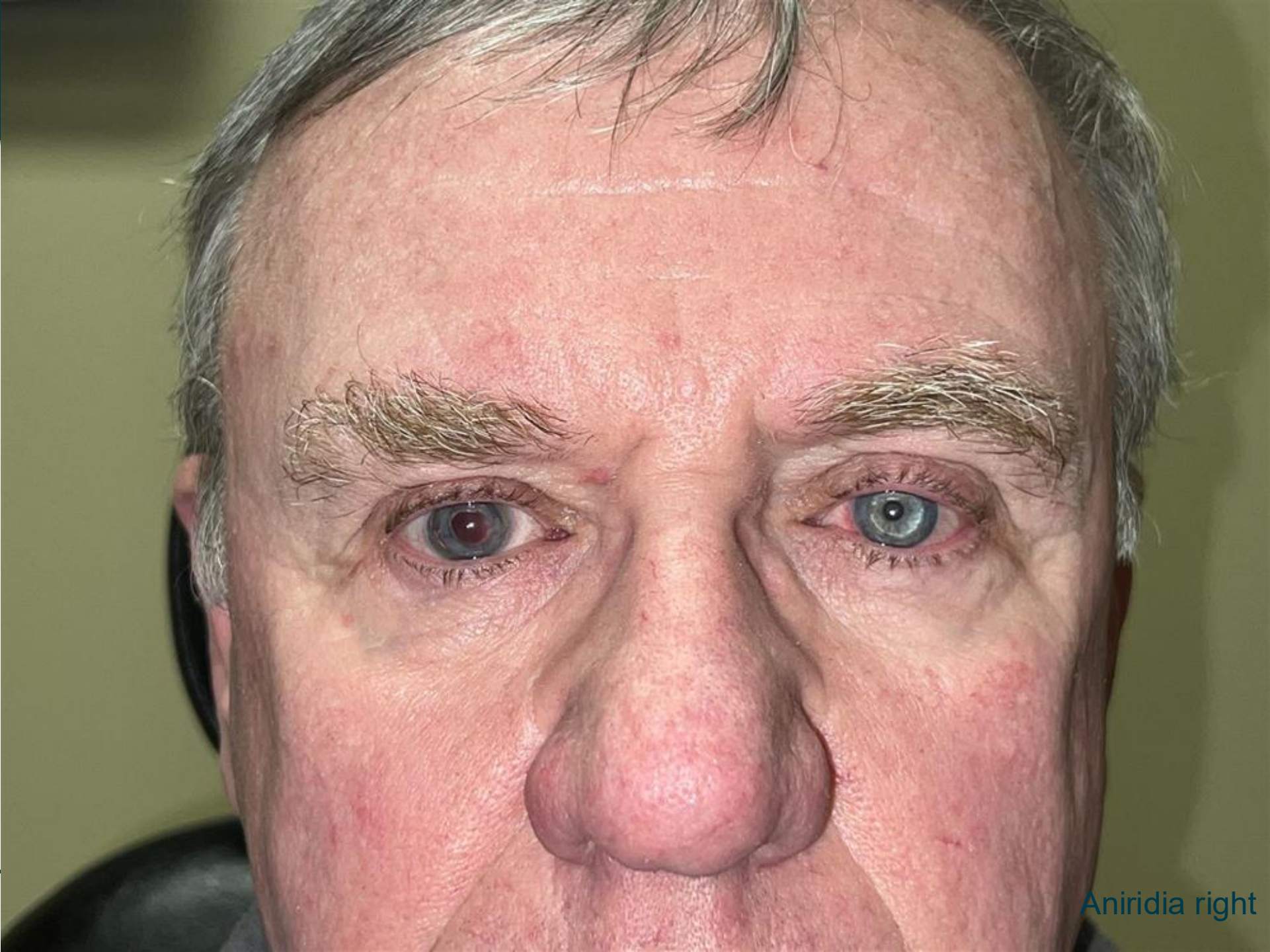Intraop artificial iris





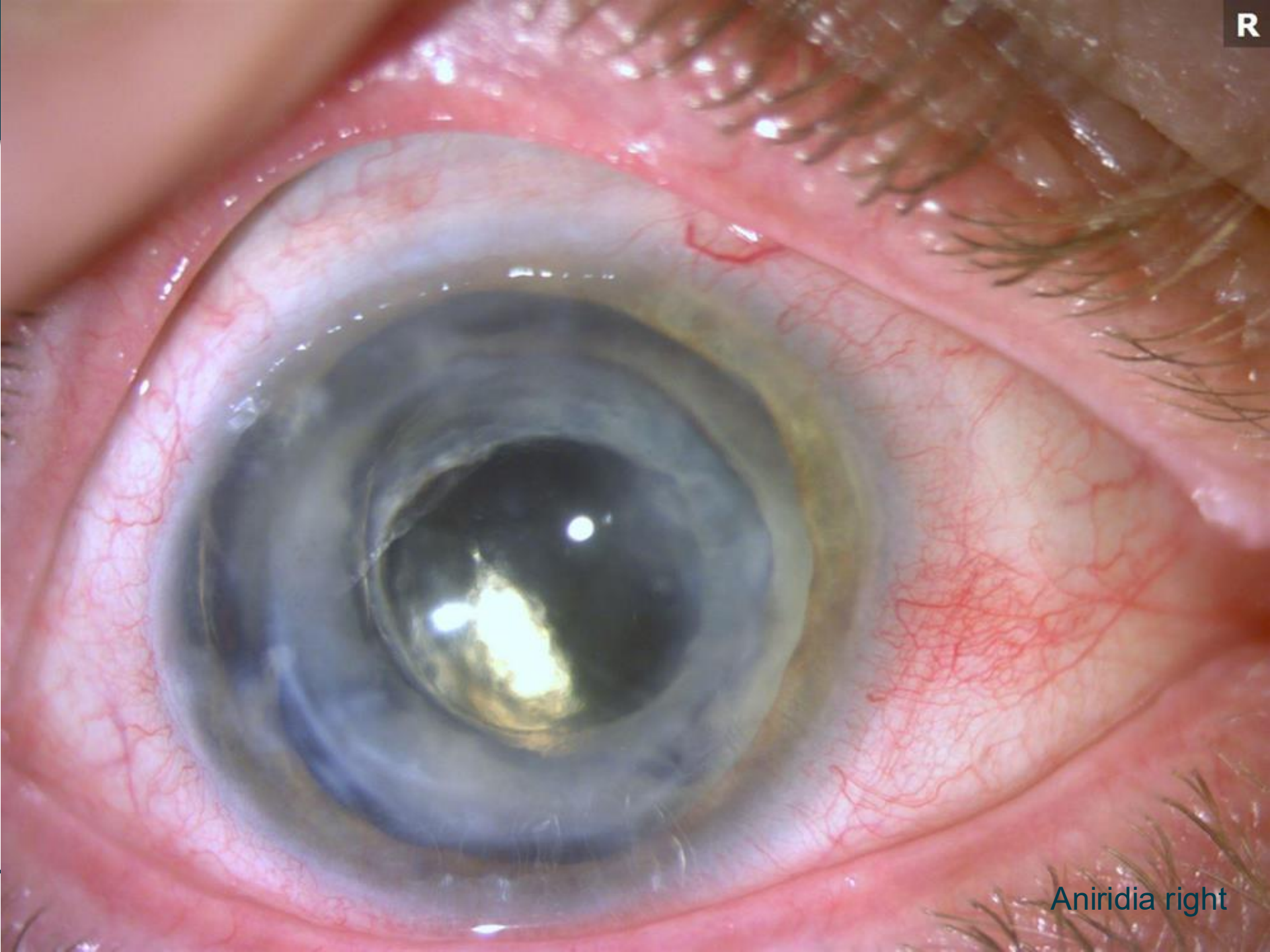Post op artificial iris





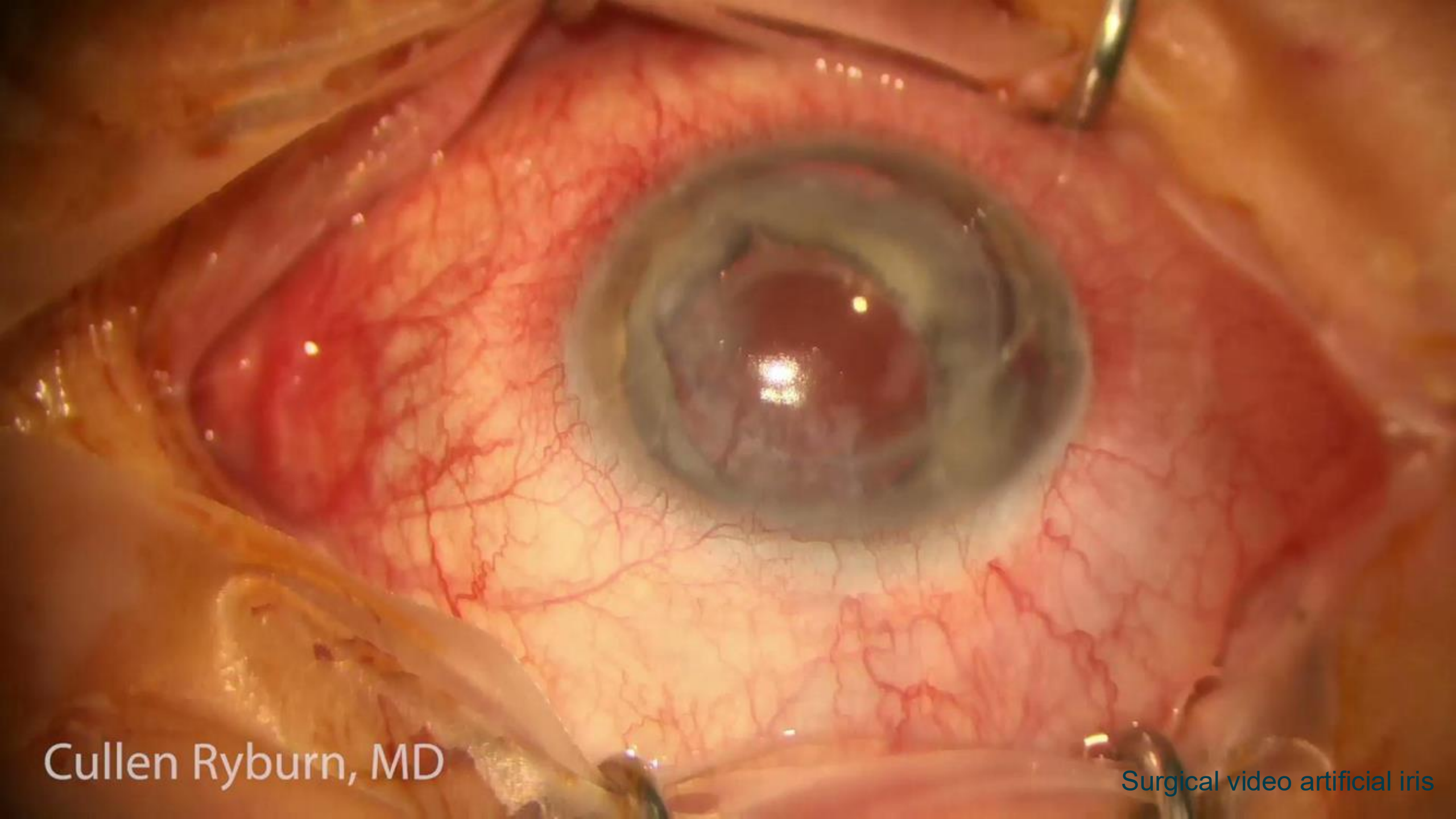
Aniridia right





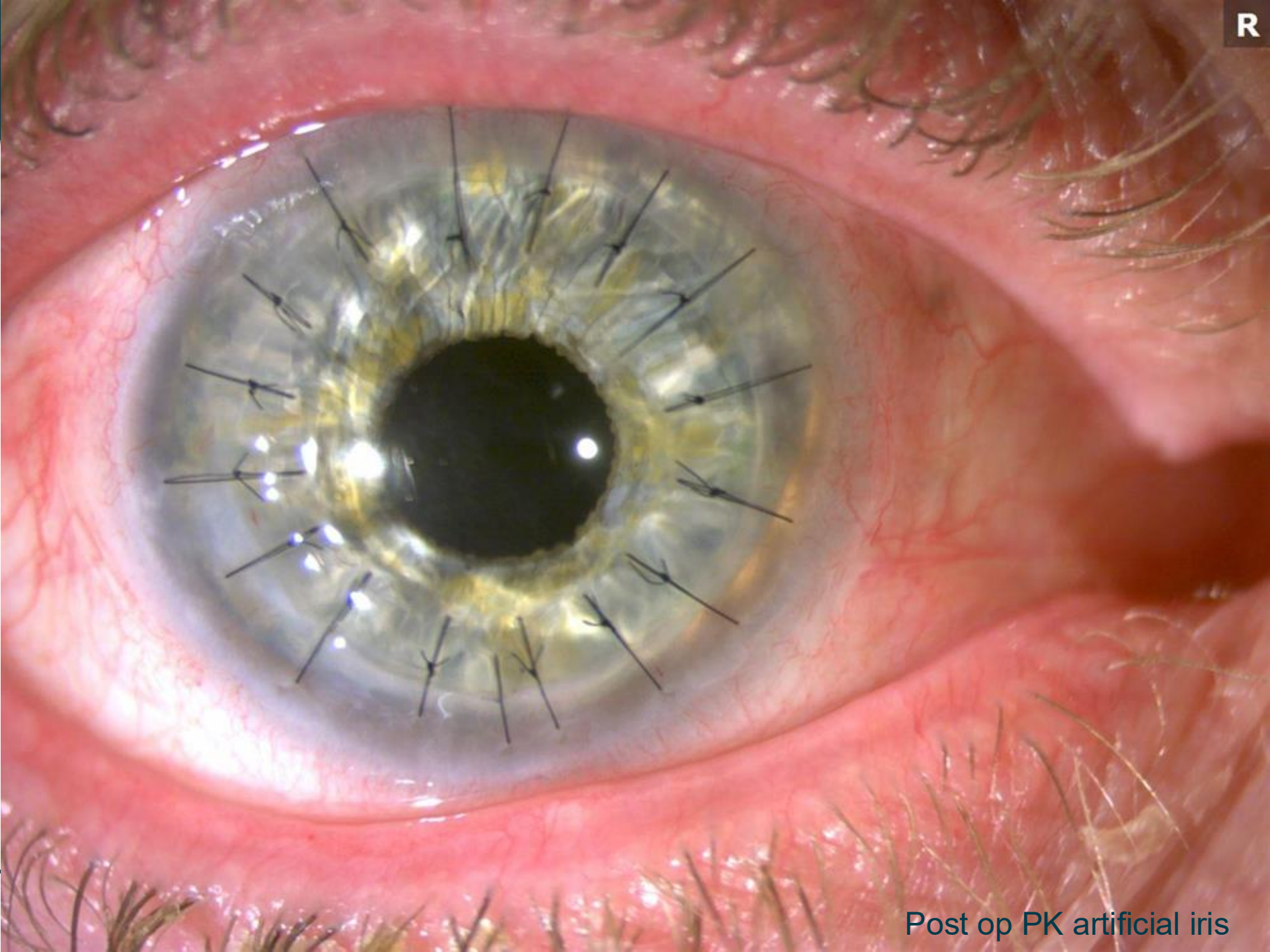
Aniridia right





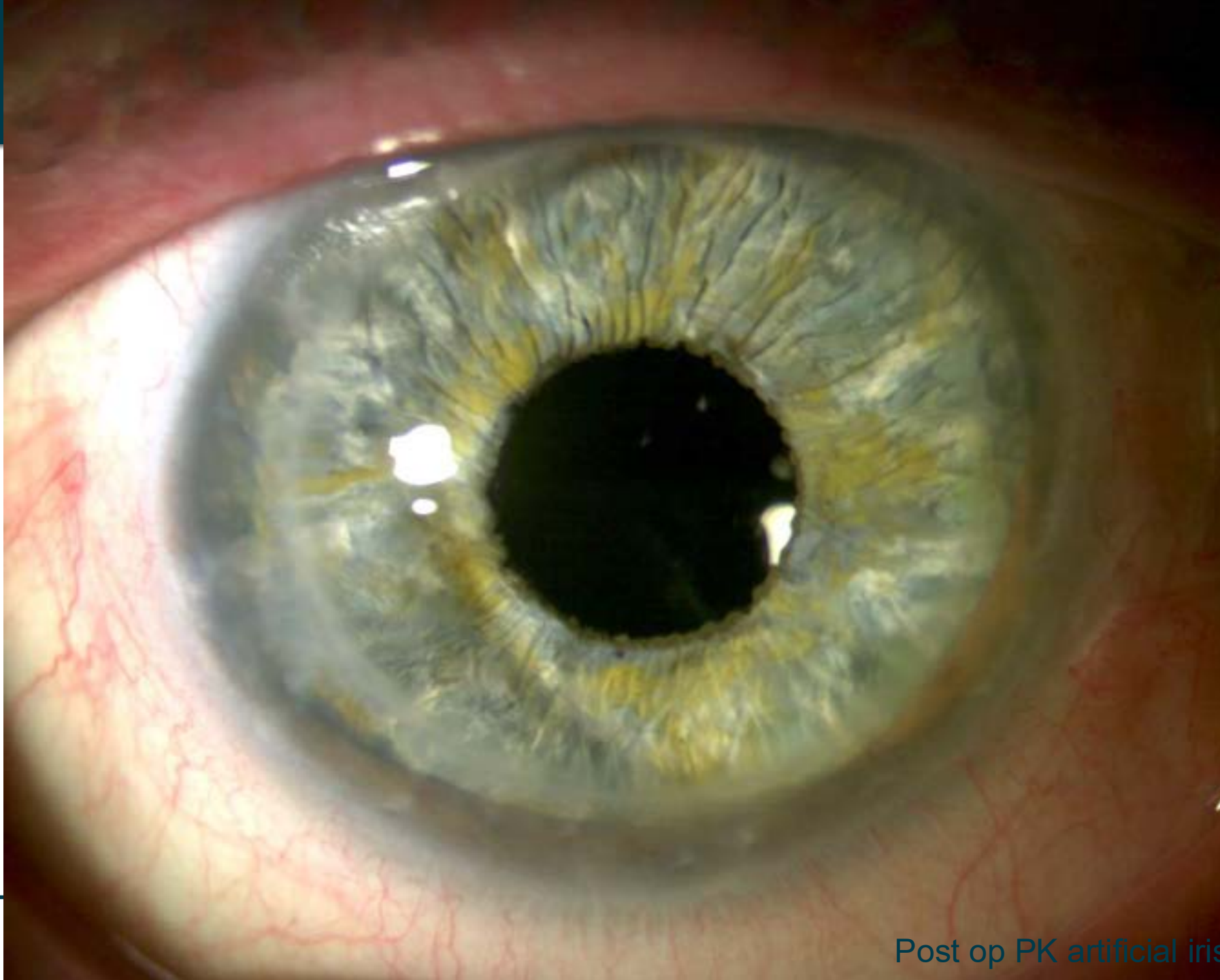Cullen Ryburn, MD

Surgical video artificial iris



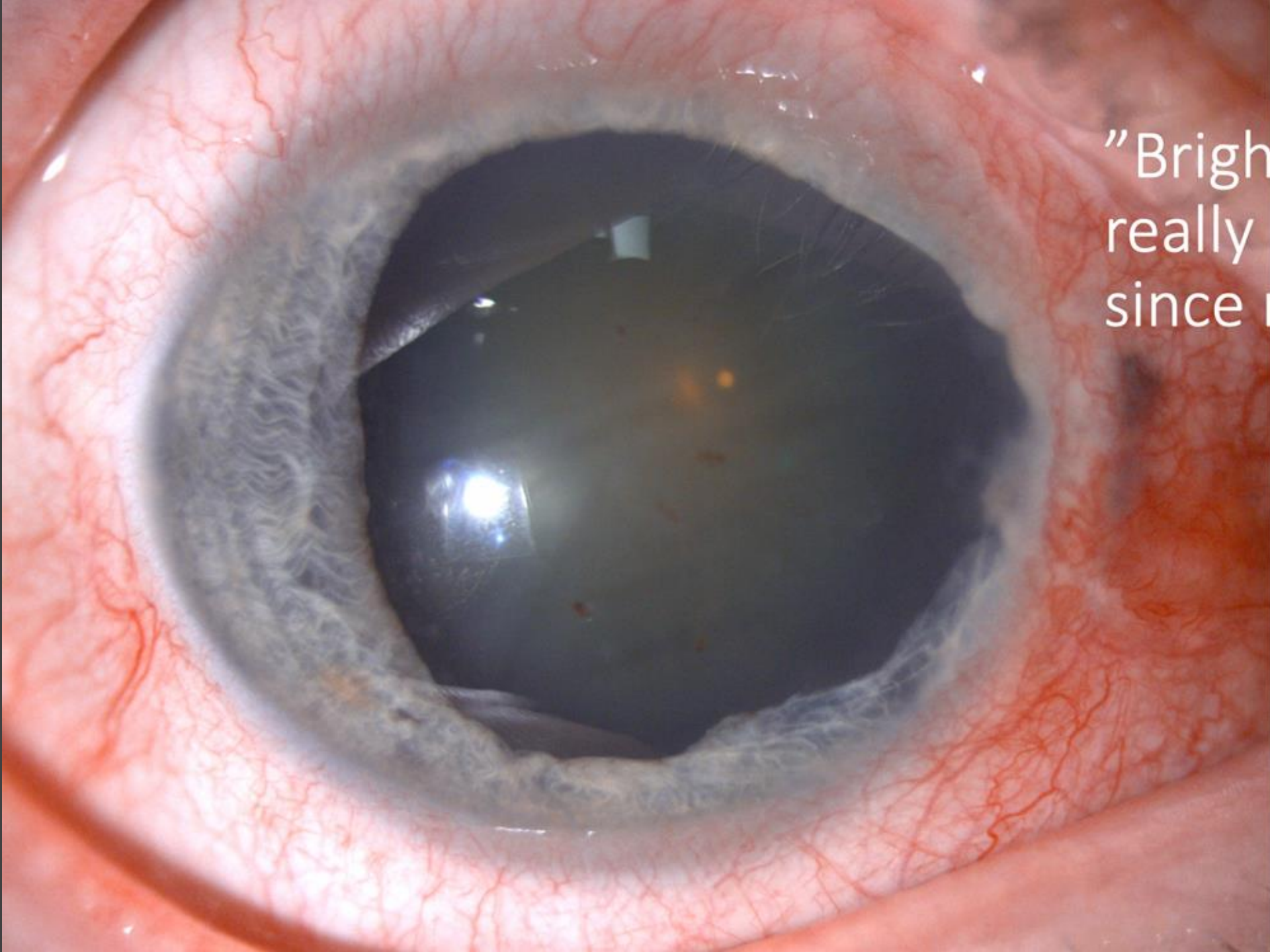
Post op PK artificial iris



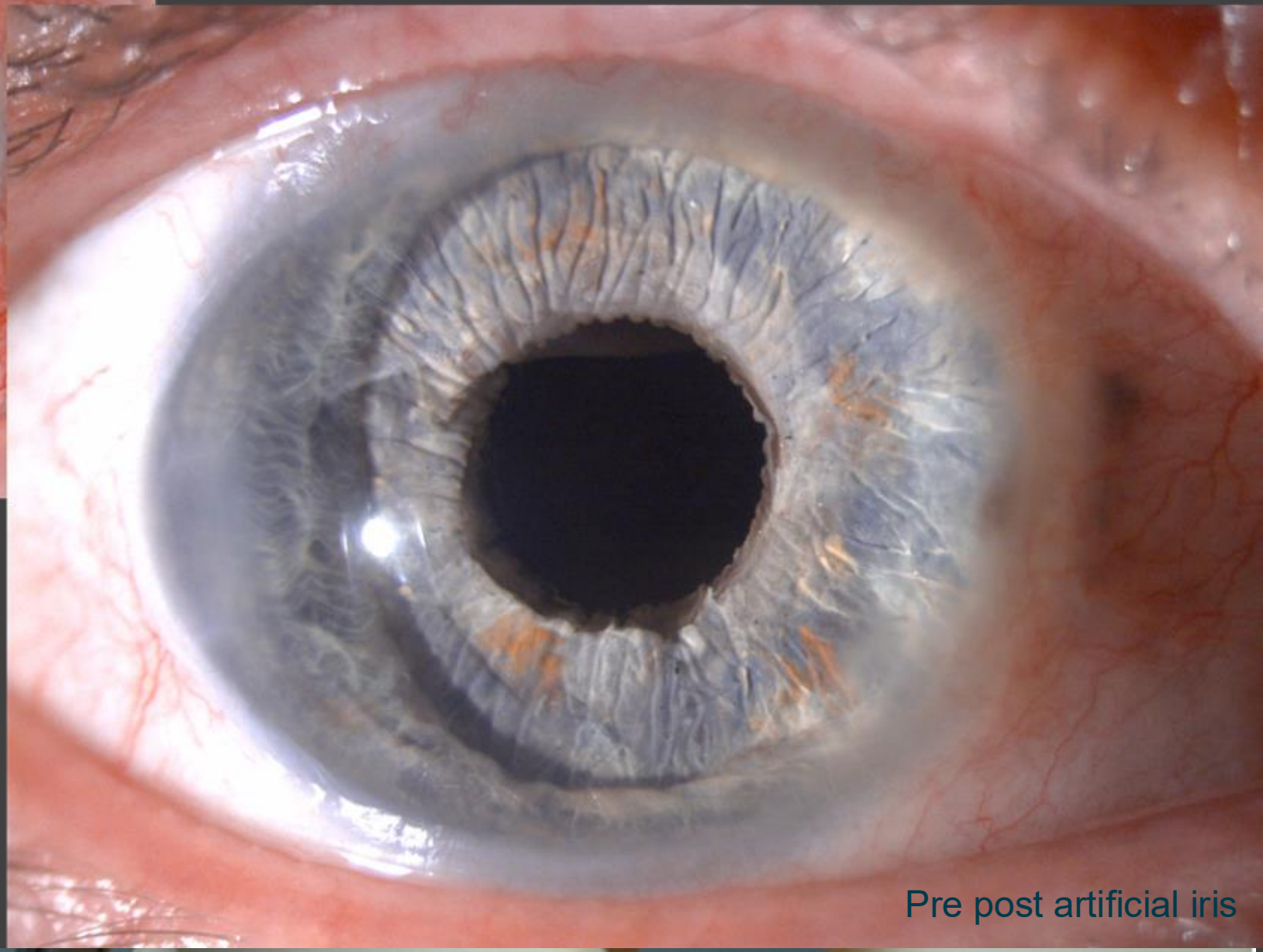
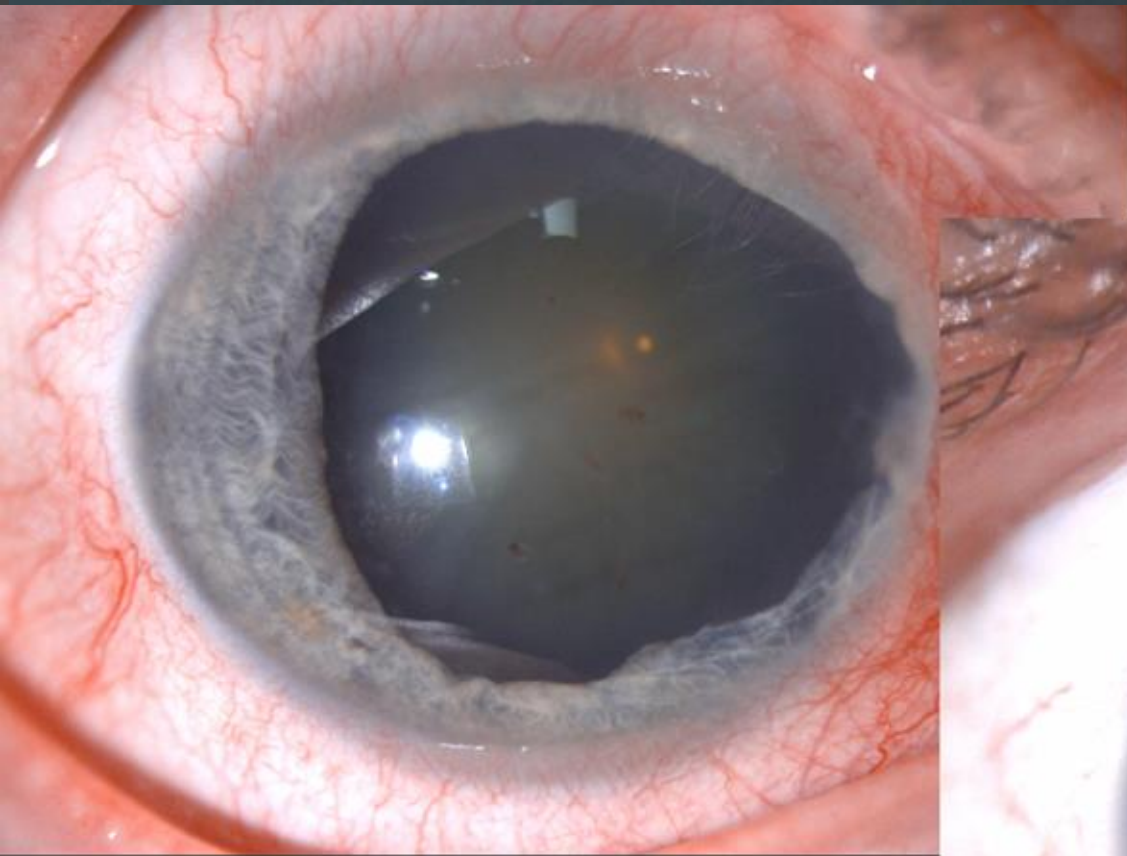


Post op PK artificial iris



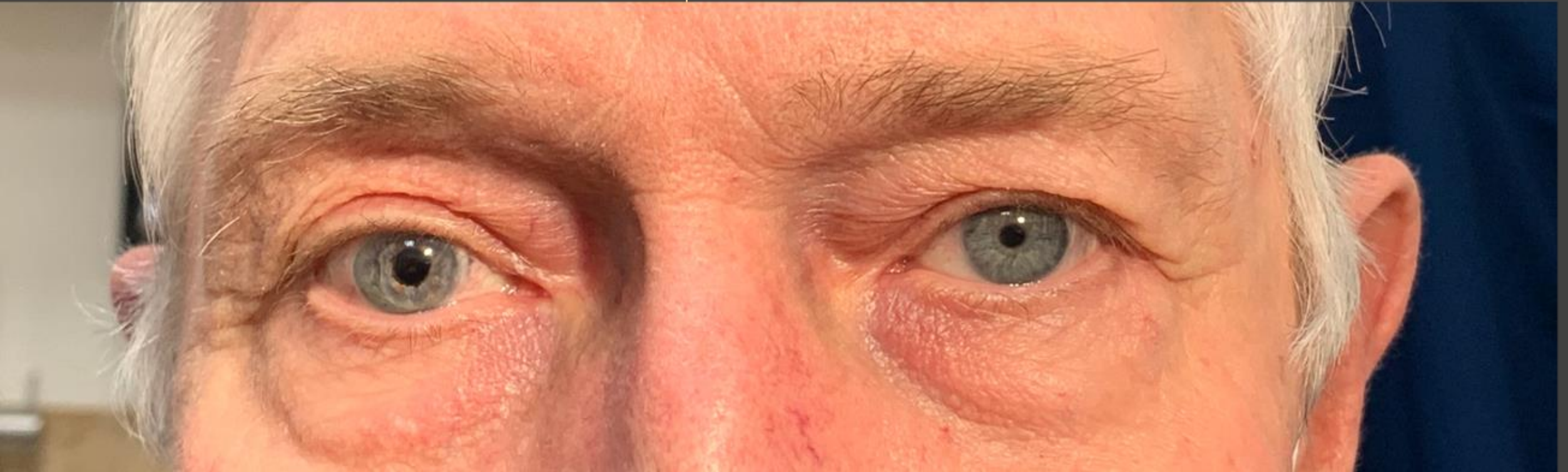

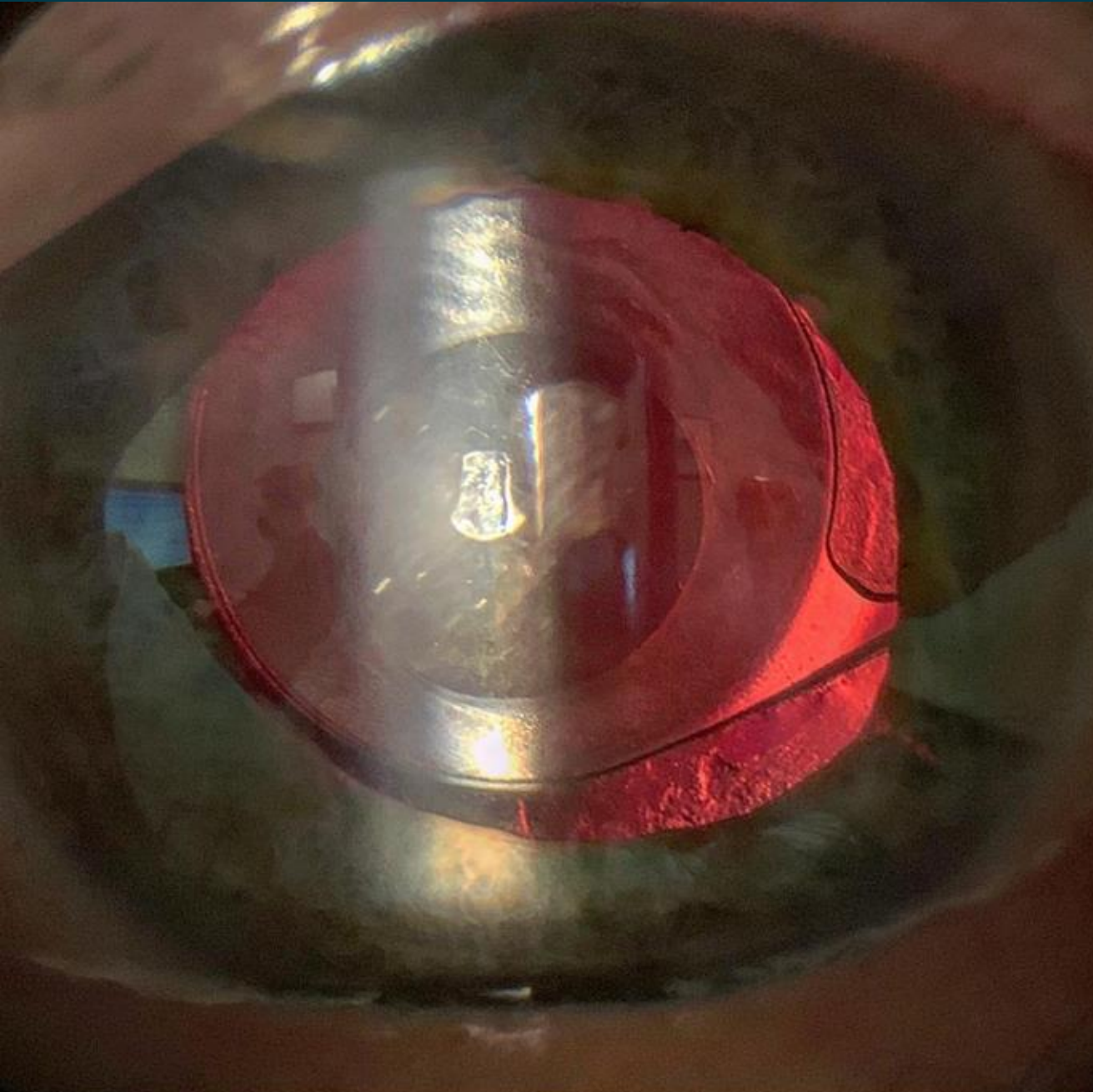
“Bright lights have really bothered me since my injury”



Pre post artificial iris

“I have my life back”





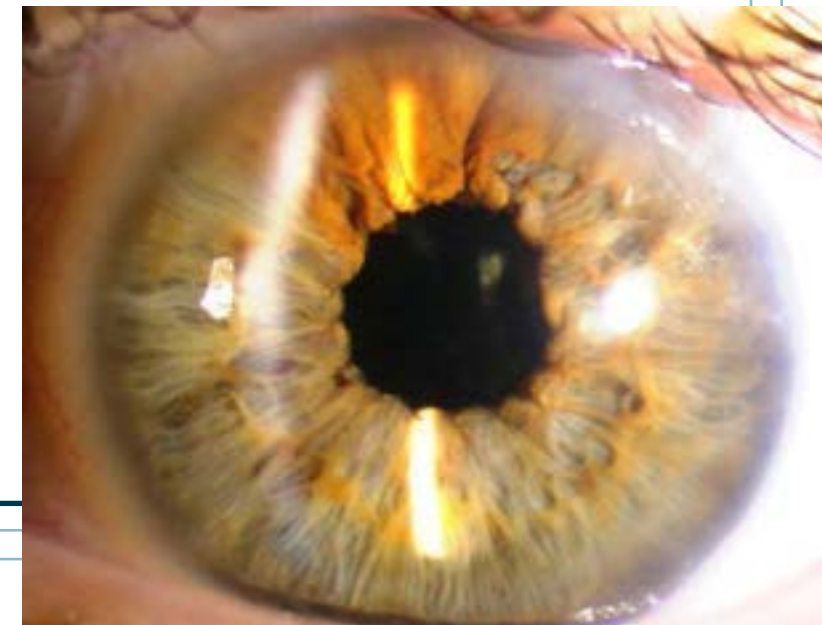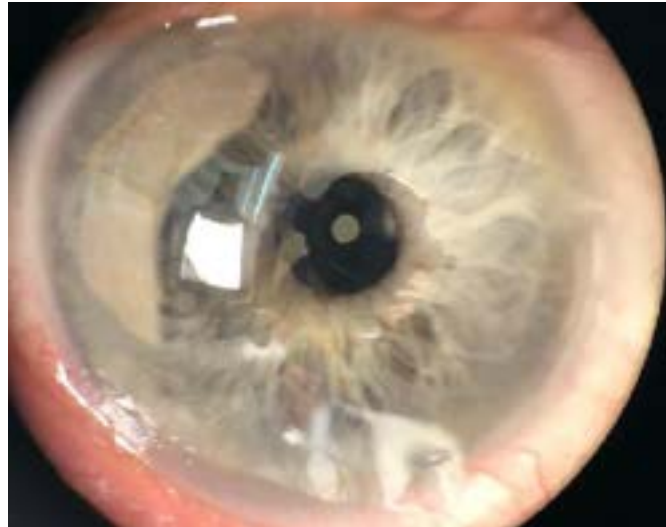Traumatic Aniridia Traumatic Mydriasis

- Onset following trauma
- Open globe
- Surgical trauma
- Floppy iris syndrome
-
- Can have extreme photophobia even with sunglasses inside
-
- Can be debilitating

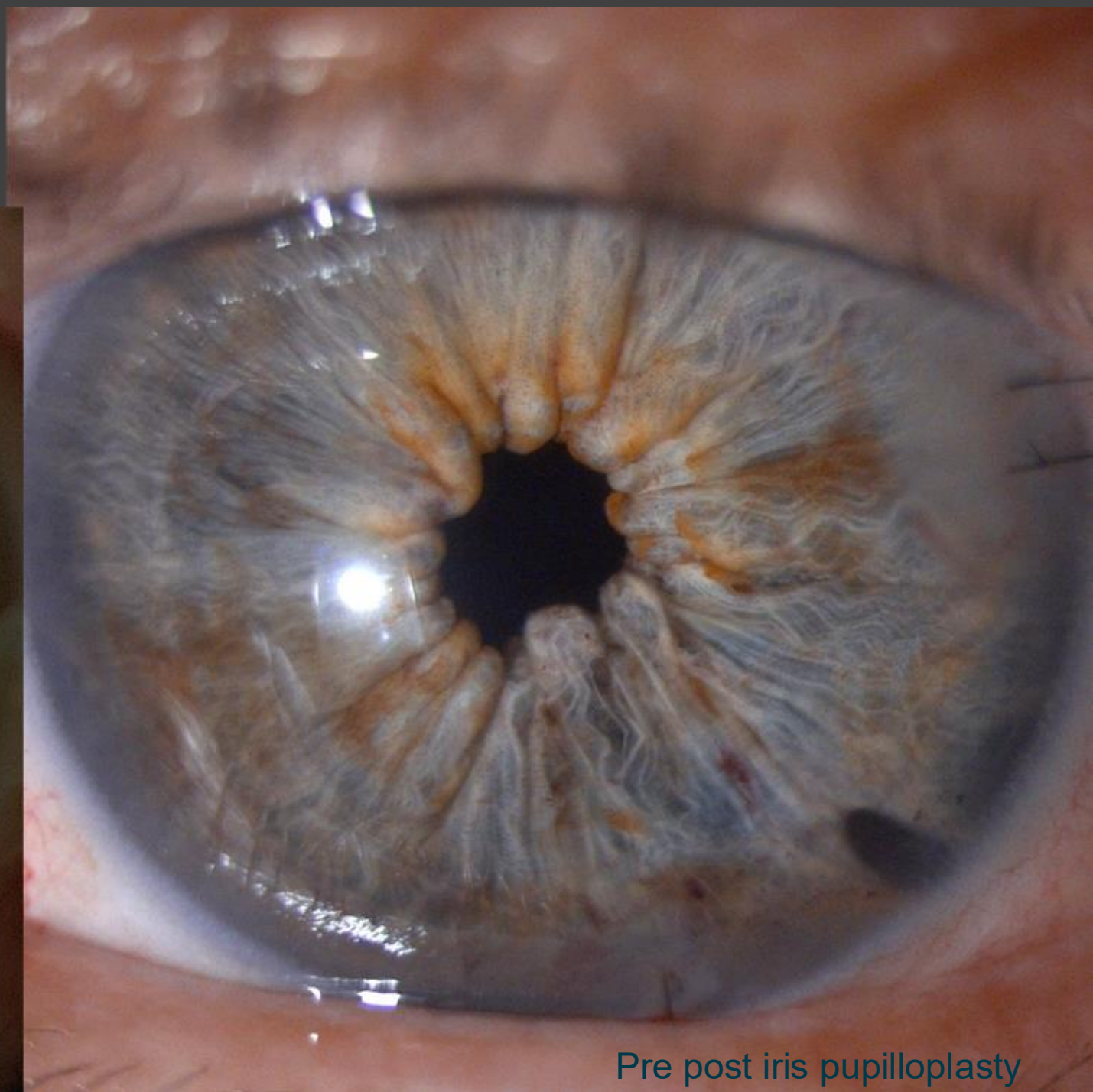
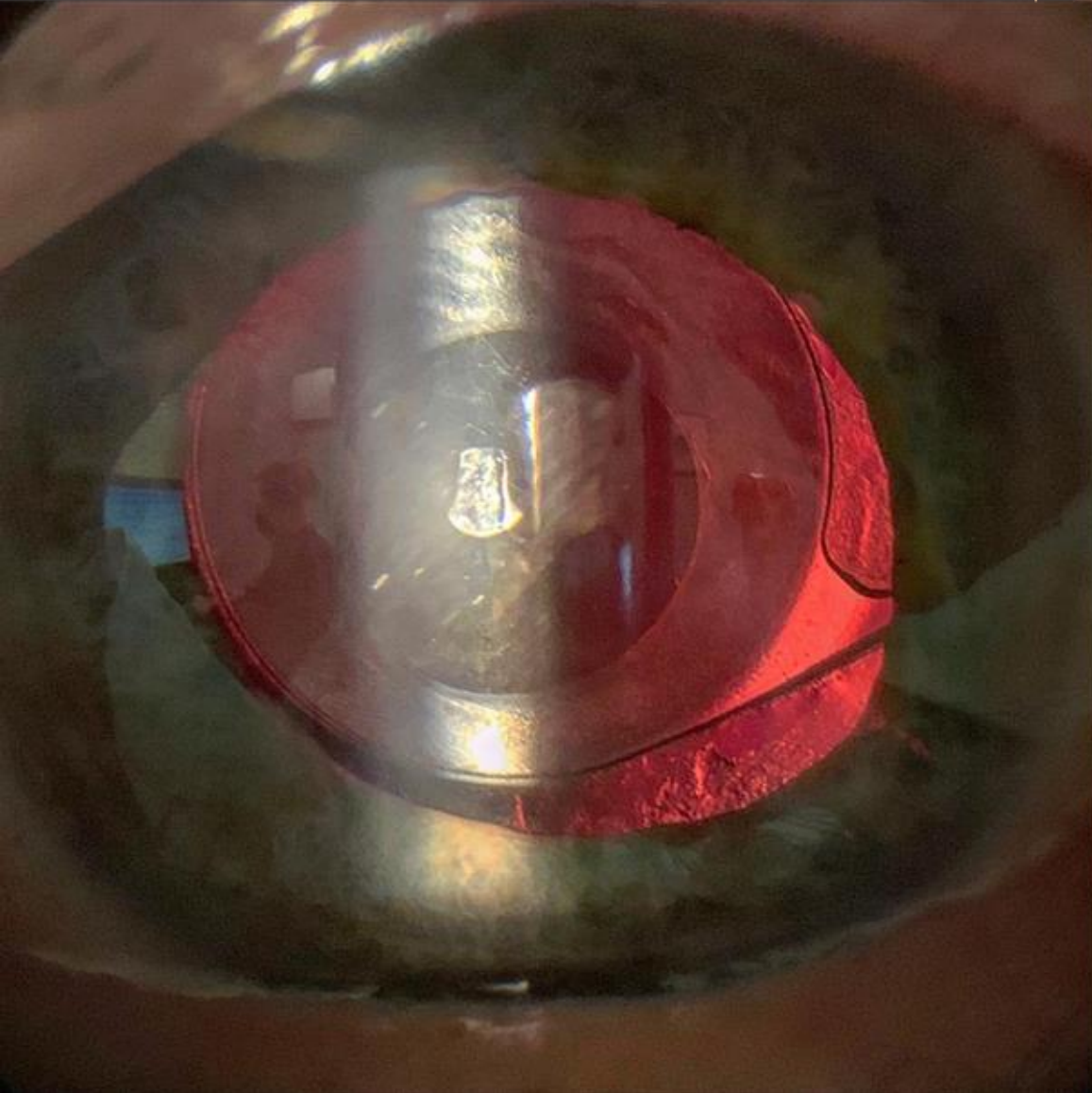


Repairing Traumatic Mydriasis

- Colored Contact Lens
- Corneal Tattoo
- Iris Cerclage
- Artificial Iris



“I can work again”



Pre post iris pupilloplasty

Vision Programs ▾ | Resources ▾ | Continuing Education ▾ | Research ▾

Resources — [VIEW ALL](#)

[Referral and Authorization Forms](#) >

[Quick Guides: Clinical Tools and Resources](#) >

[See & Do and Back-to-Back](#) >

[Billing Information](#) >

[Handouts](#) >

[Order Materials](#) >

[Vancethompsonvision.com/OD](https://vancethompsonvision.com/OD)

THE VANCE THOMPSON VISION

**WORLD-CLASS
VISION CARE
EVERY PATIENT**



Strong relationships with local OD
community

We love feedback!

Let us know how we can help!



Looking forward to the future!



Cullen Ryburn, MD

Cell: 806-543-1440

cullen.ryburn@vancethompsonvision.com

